Pelvis/Perineum

Pelvis/Perineum

Key Boney Landmarks

- Pubic crest
- Pectineal and arcuate lines
- Sacral promontory

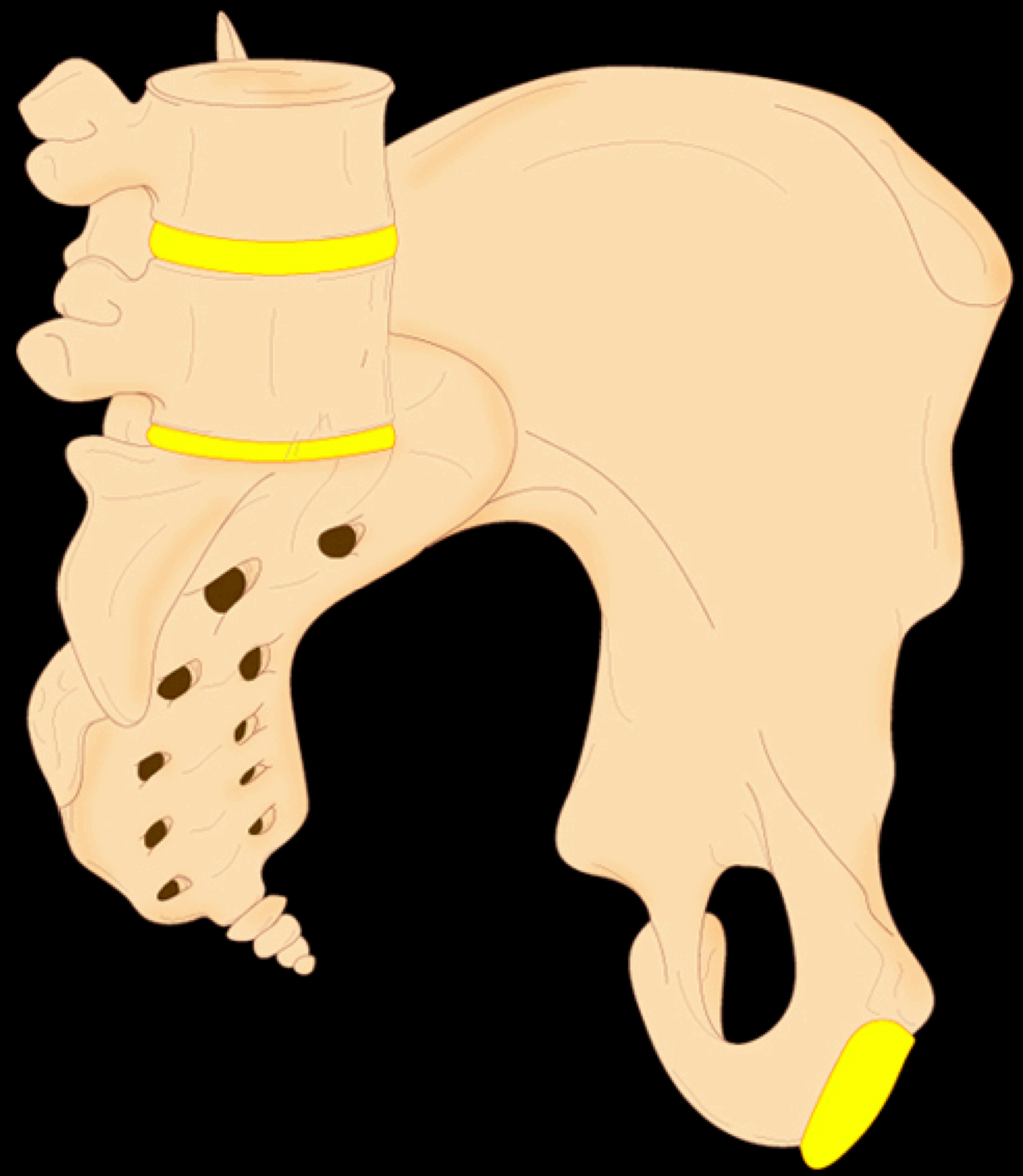

Pelvis/Perineum

Key Boney Landmarks

- Inferior pubic ramus
- Ischial ramus
- Ischial tuberosity

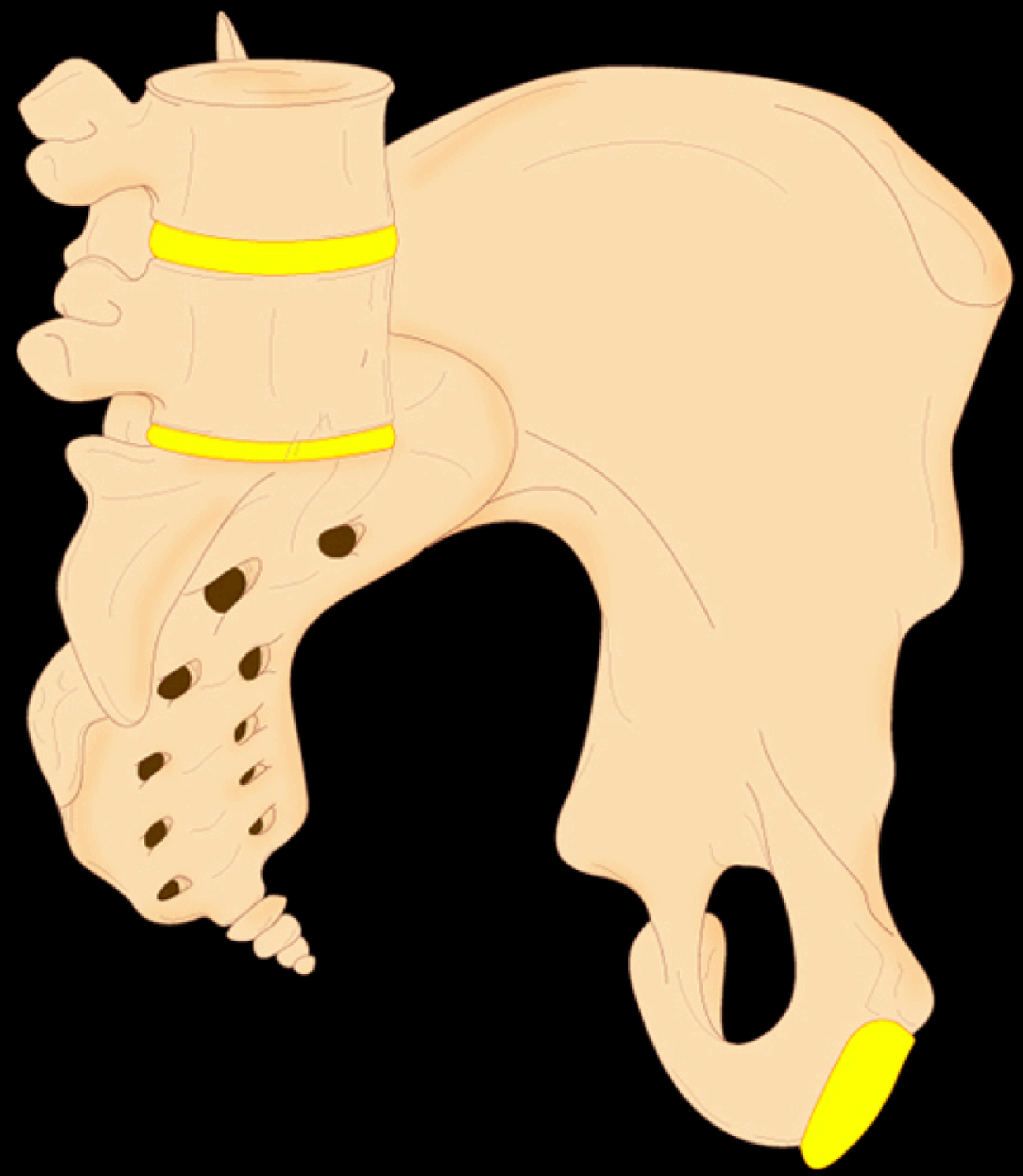

Pelvis/Perineum

Key Boney Landmarks

- Ischial spine
- Greater sciatic notch
- Lesser sciatic notch

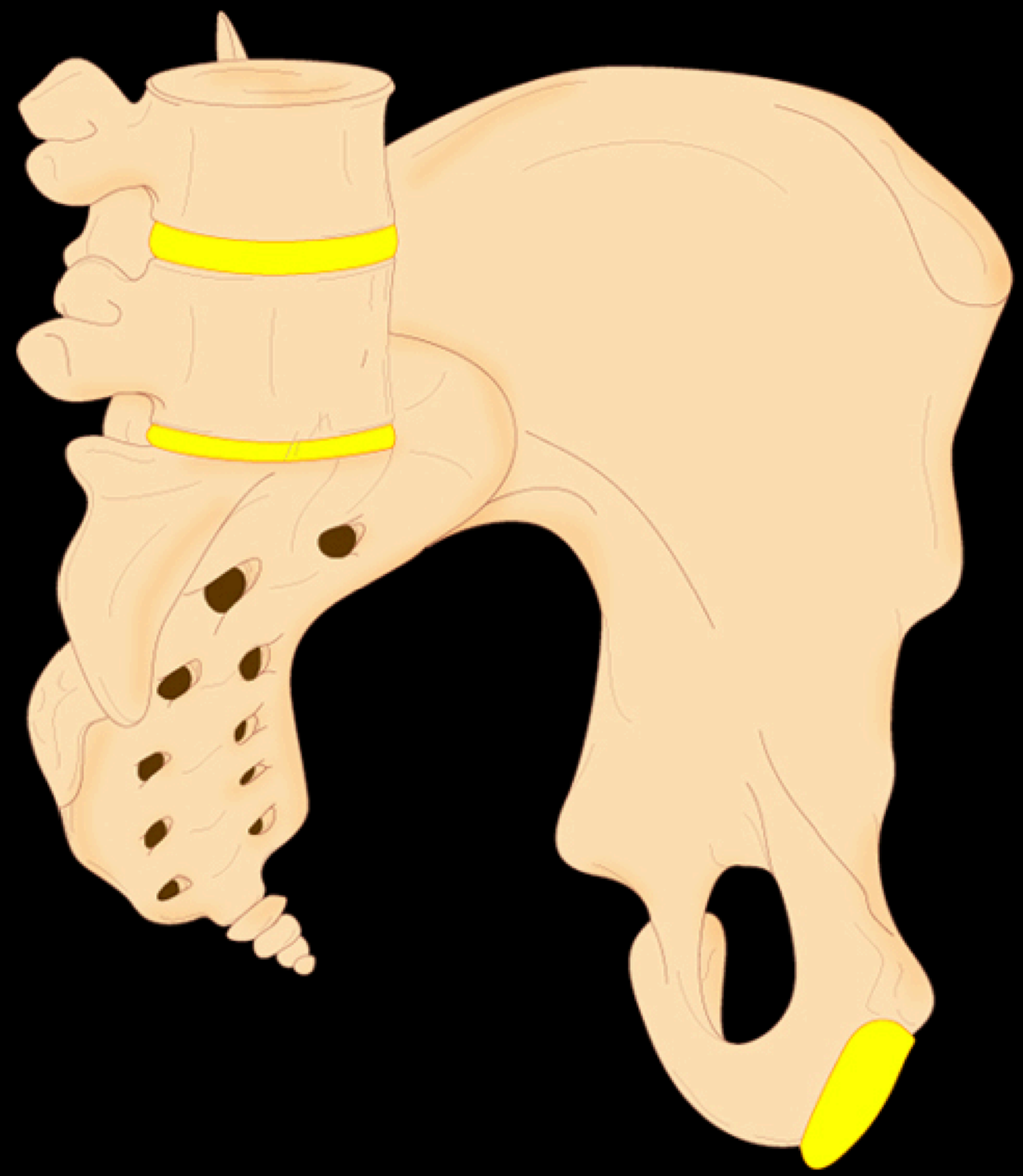

The Pelvis

Ligaments

Sacrospinous ligament

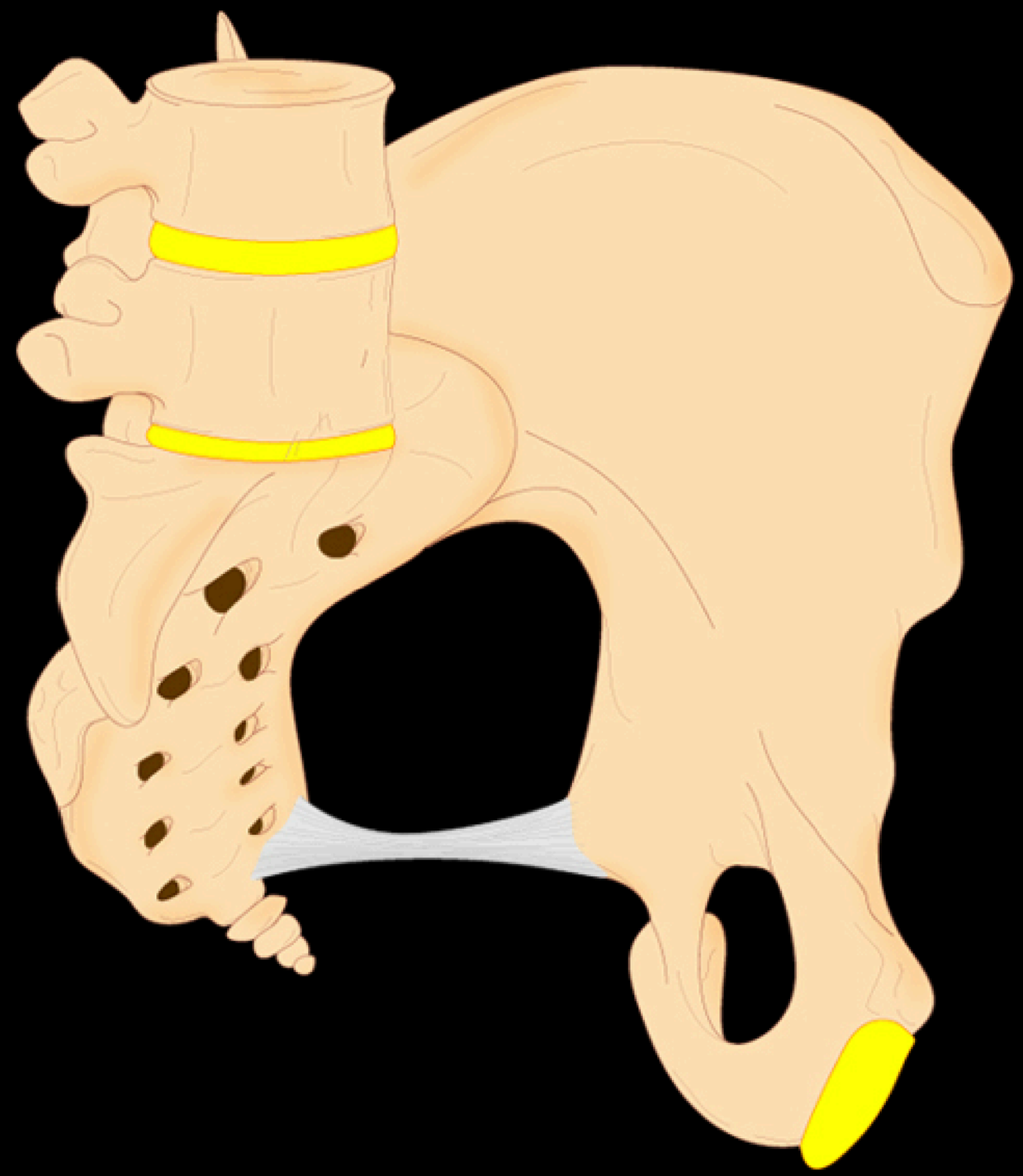

The Pelvis

Ligaments

Sacrotuberous ligament

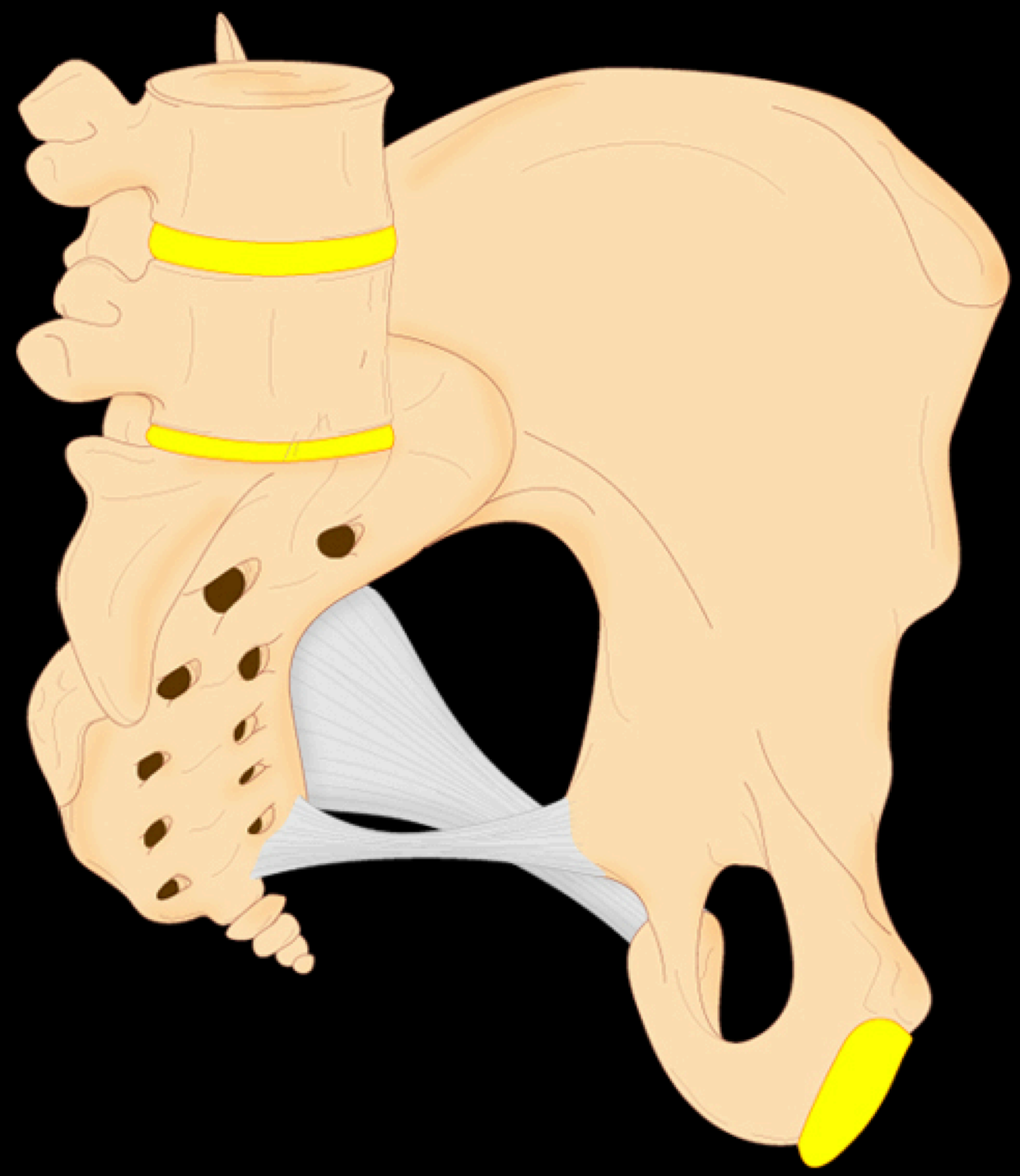

Boundary Lines

Pelvic inlet versus pelvic outlet

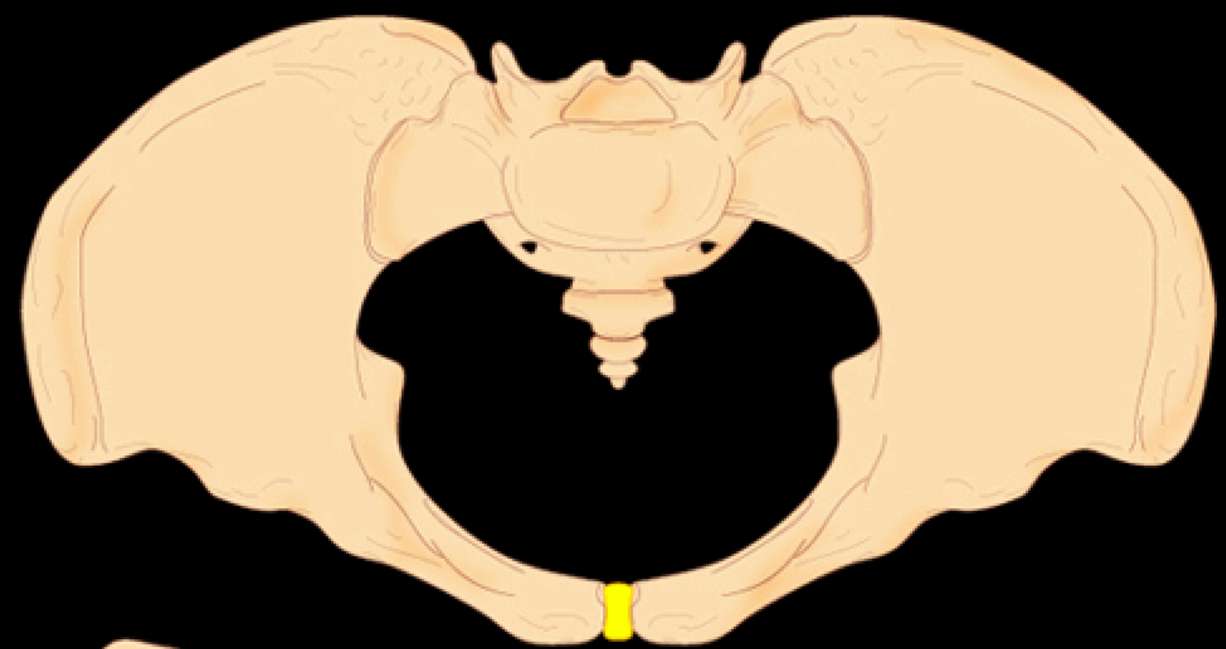

Boundary Lines

Pelvic inlet versus pelvic outlet

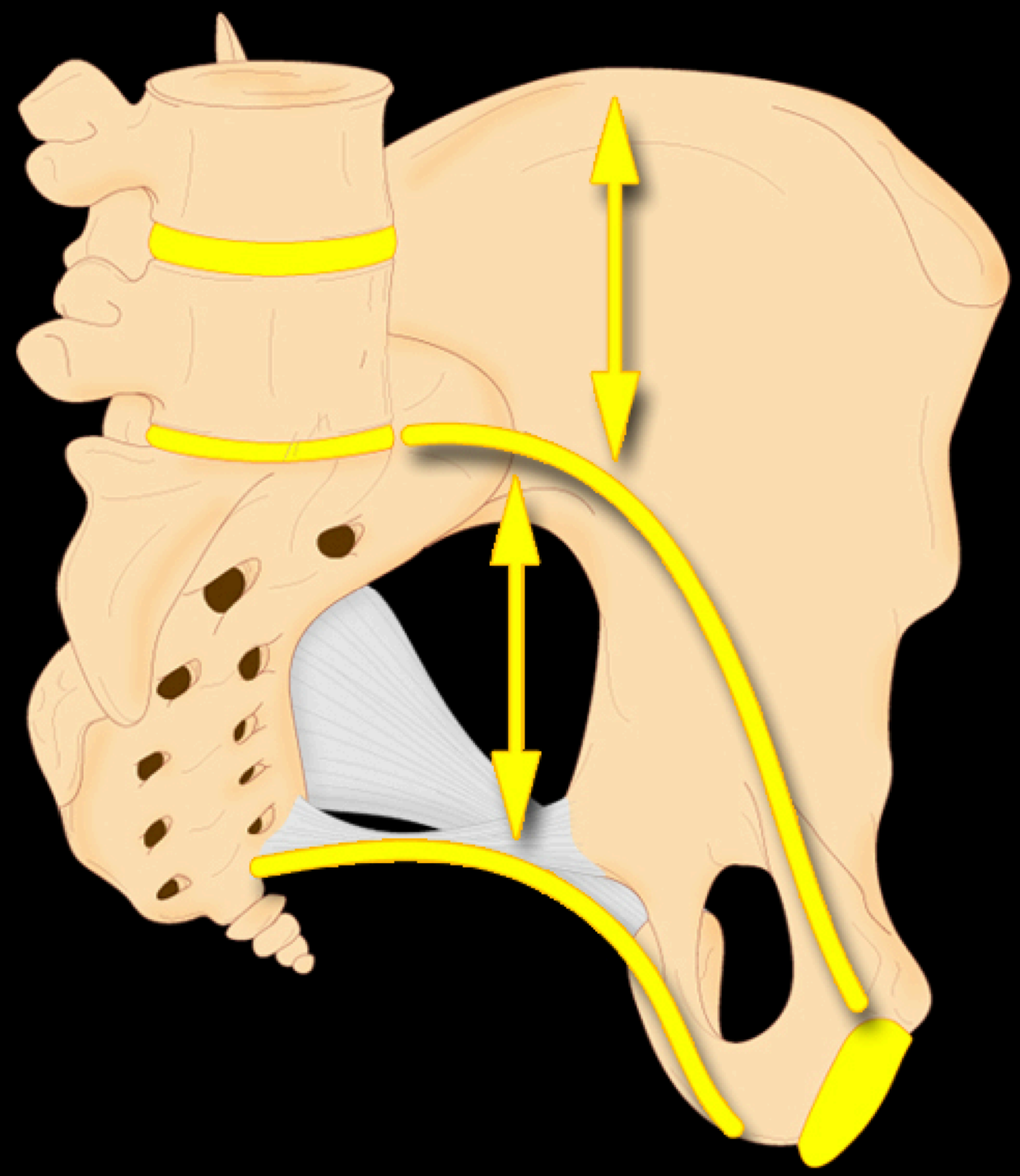

Pelvis/Perineum

Regions

False pelvis versus true pelvis

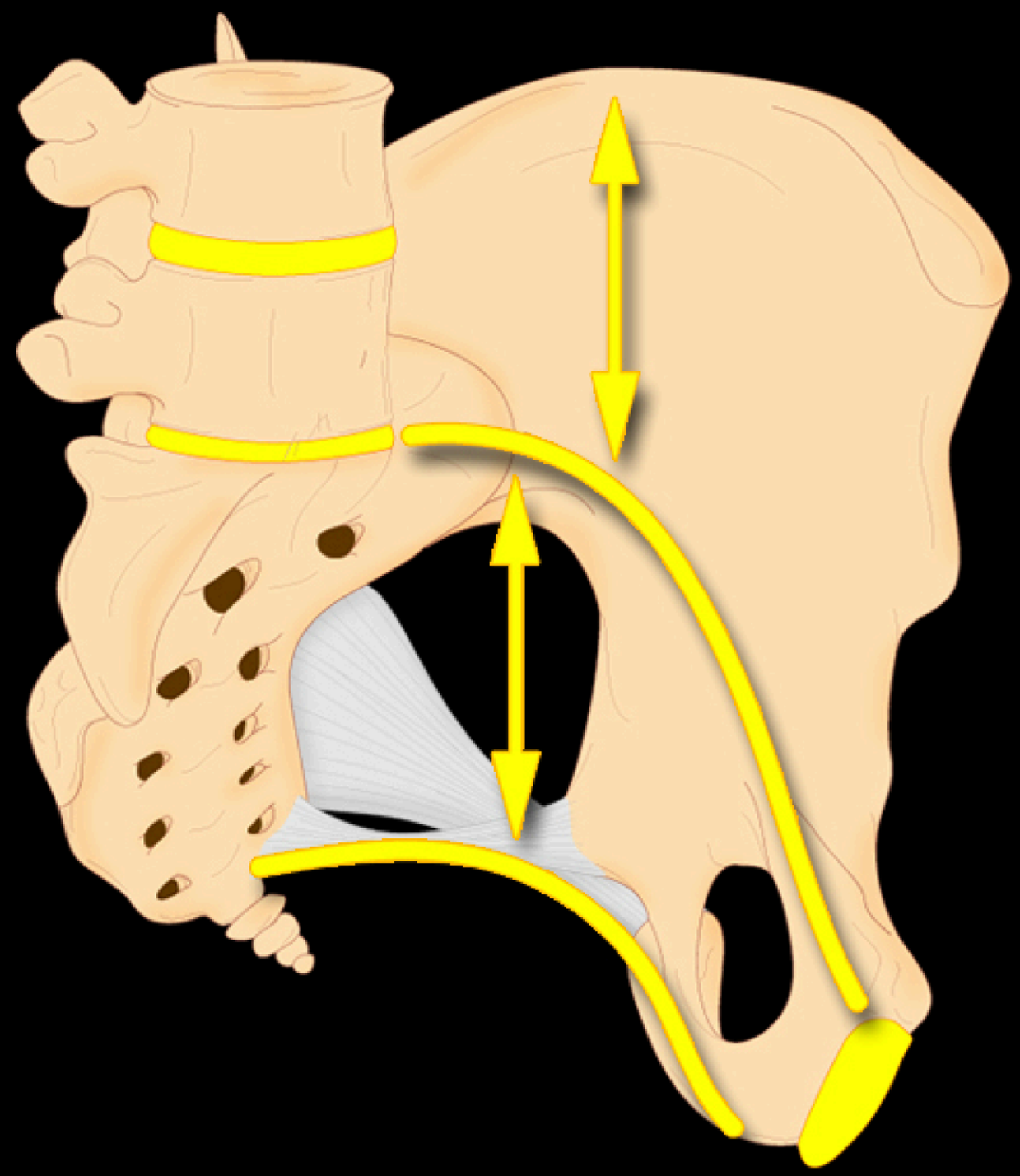

Pelvis/Perineum

Sexual Differences

Male Versus Female

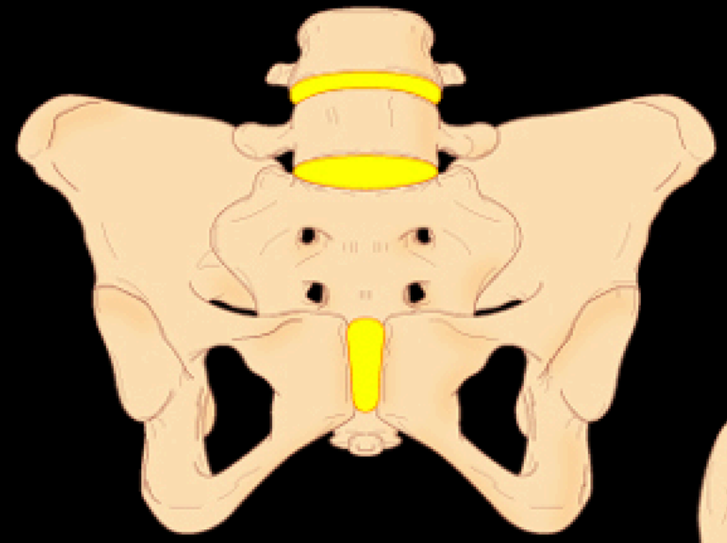

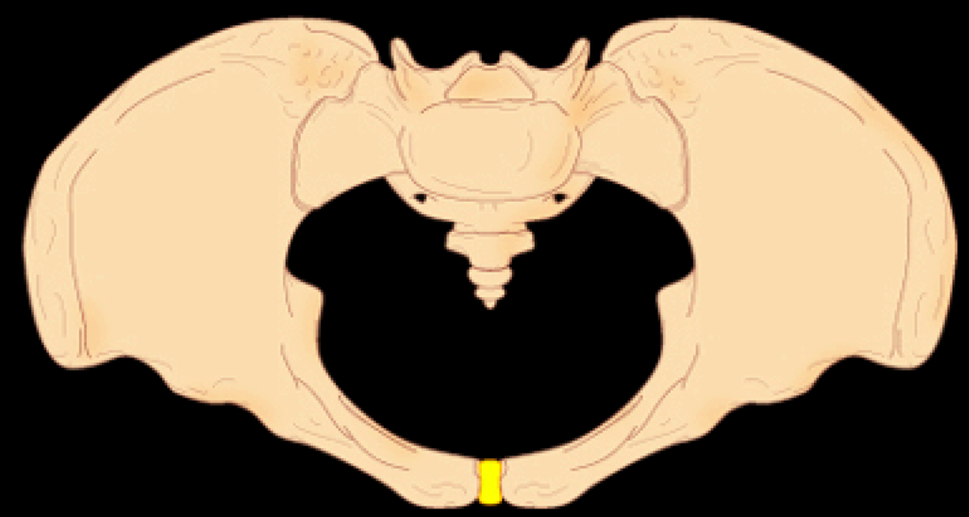

Pelvis/Perineum

Sexual Differences

Male Versus Female

Body Wall Muscle Pattern

Similarities to thorax and abdomen

Variations or differences



Perineal Triangles

Urogenital versus anal triangle

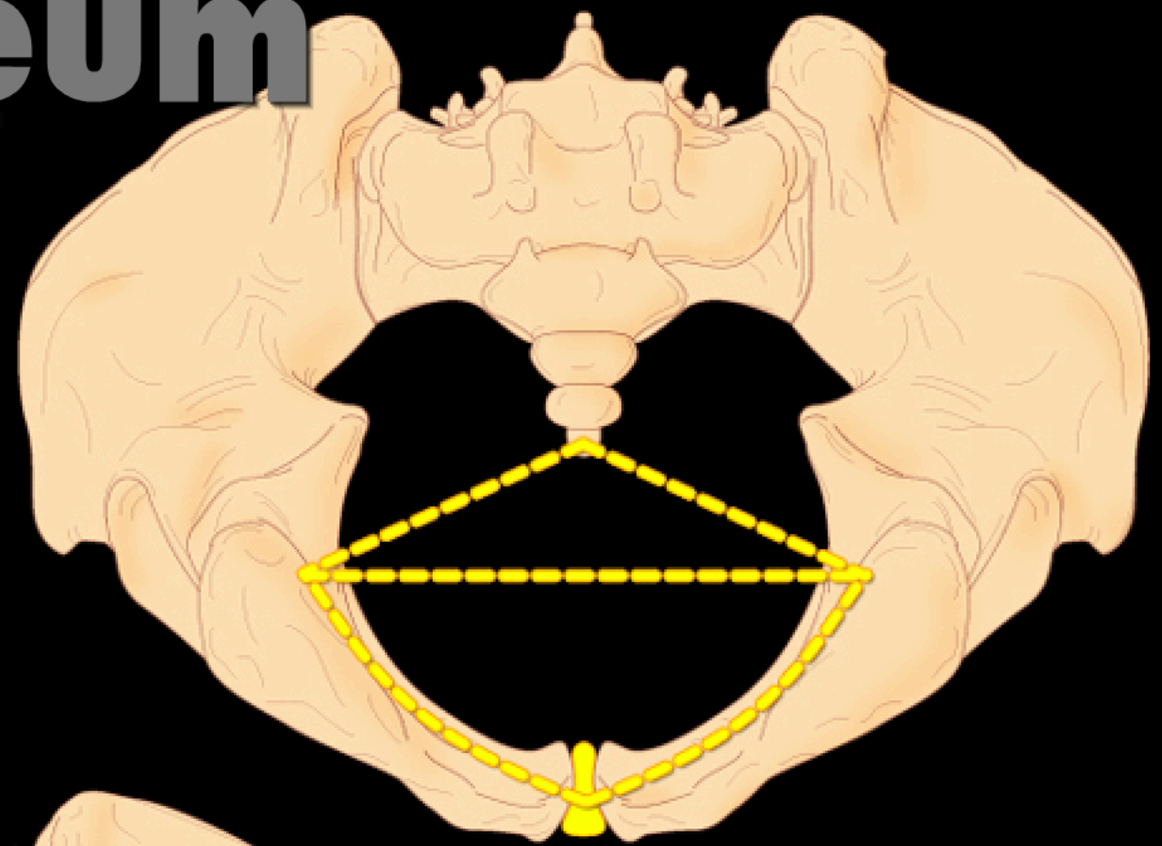

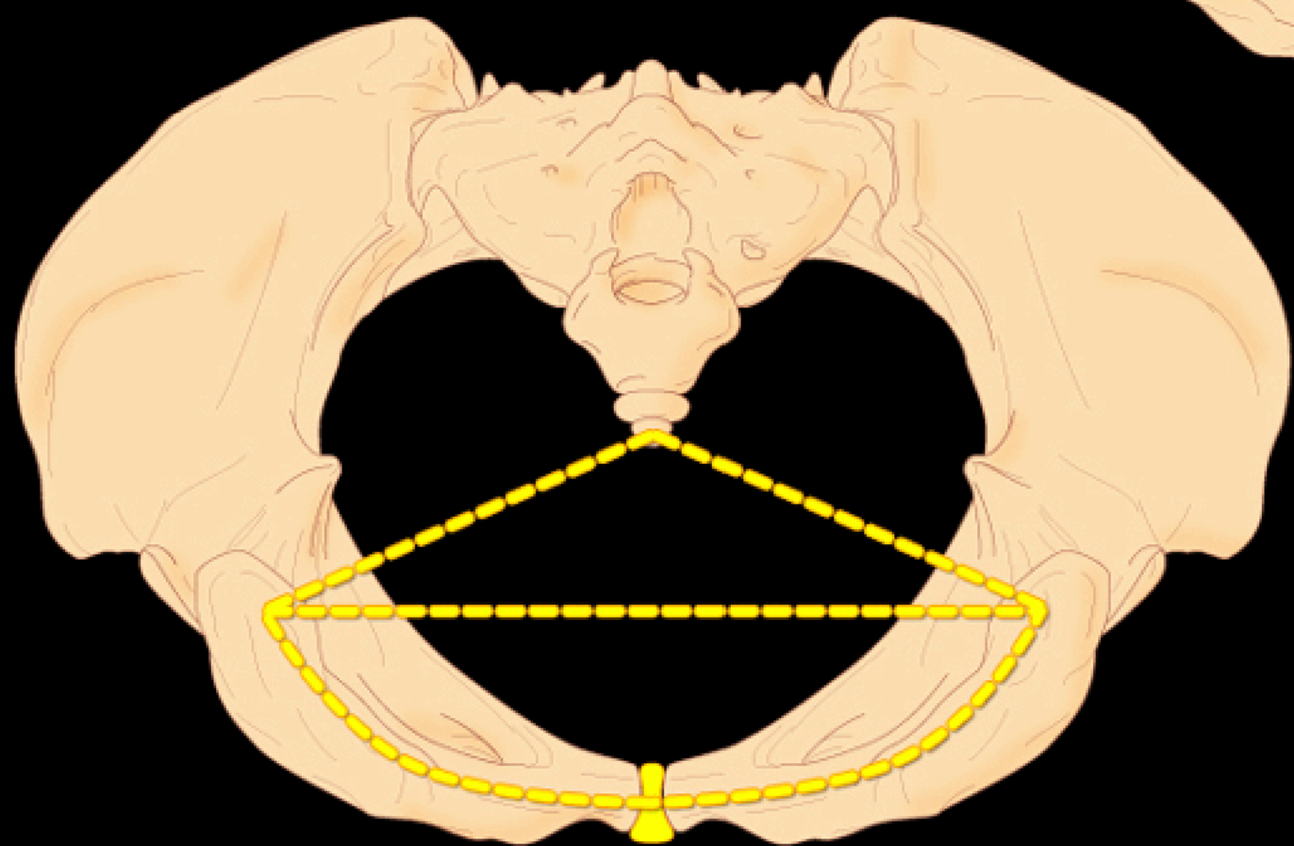

Body Wall Muscle Pattern

Remember the basic pattern!!

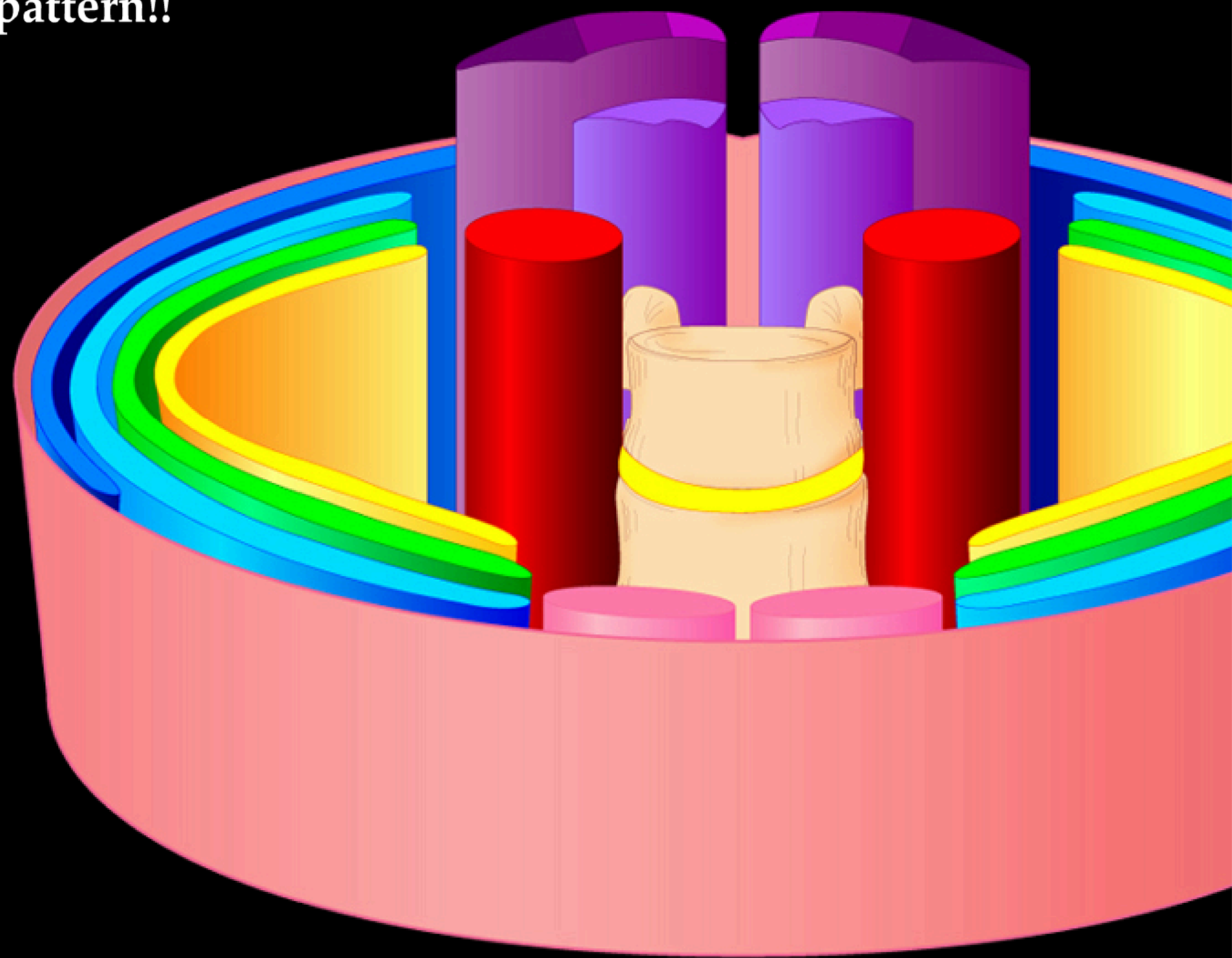

Ventral Musculature

Rectus abdominis muscle

Terminates - not present

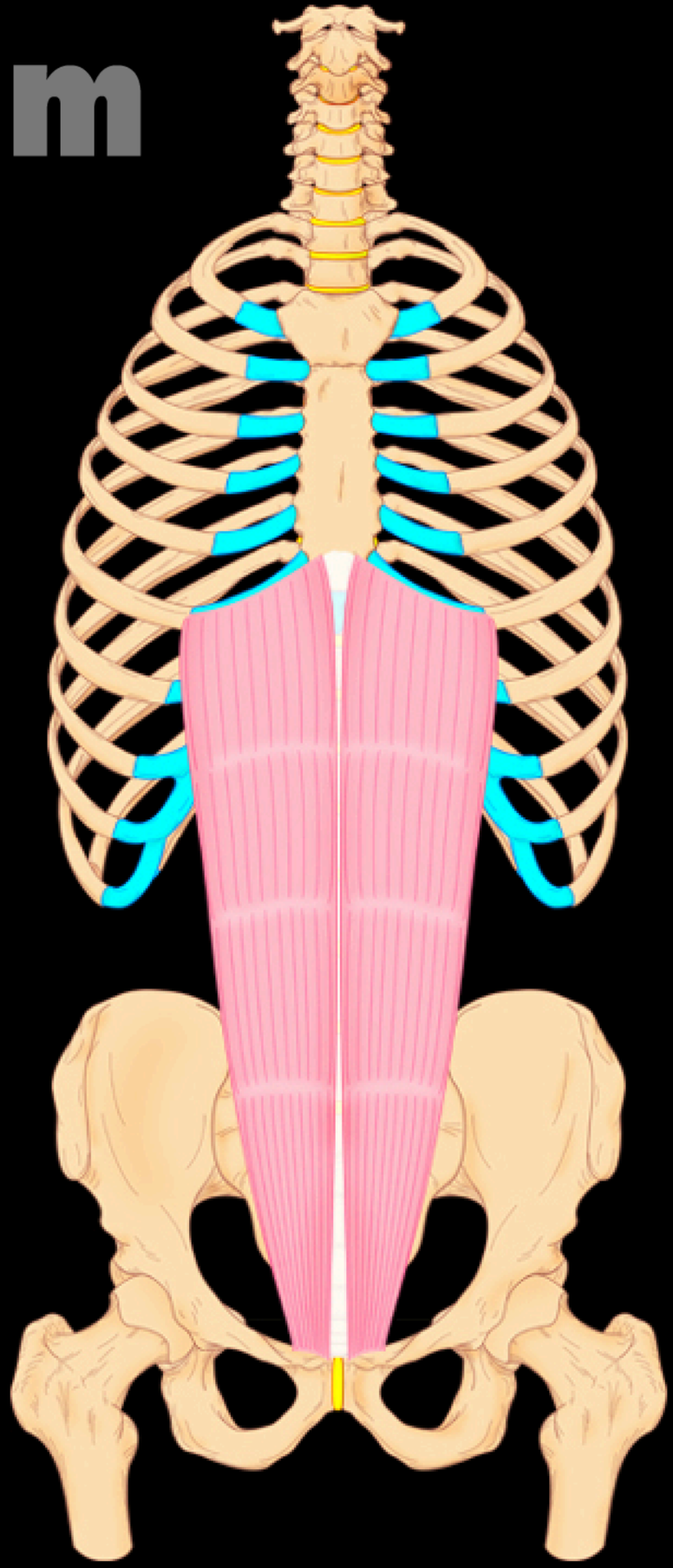

Subvertebral Musculature

Psoas minor muscle

Terminates - not present

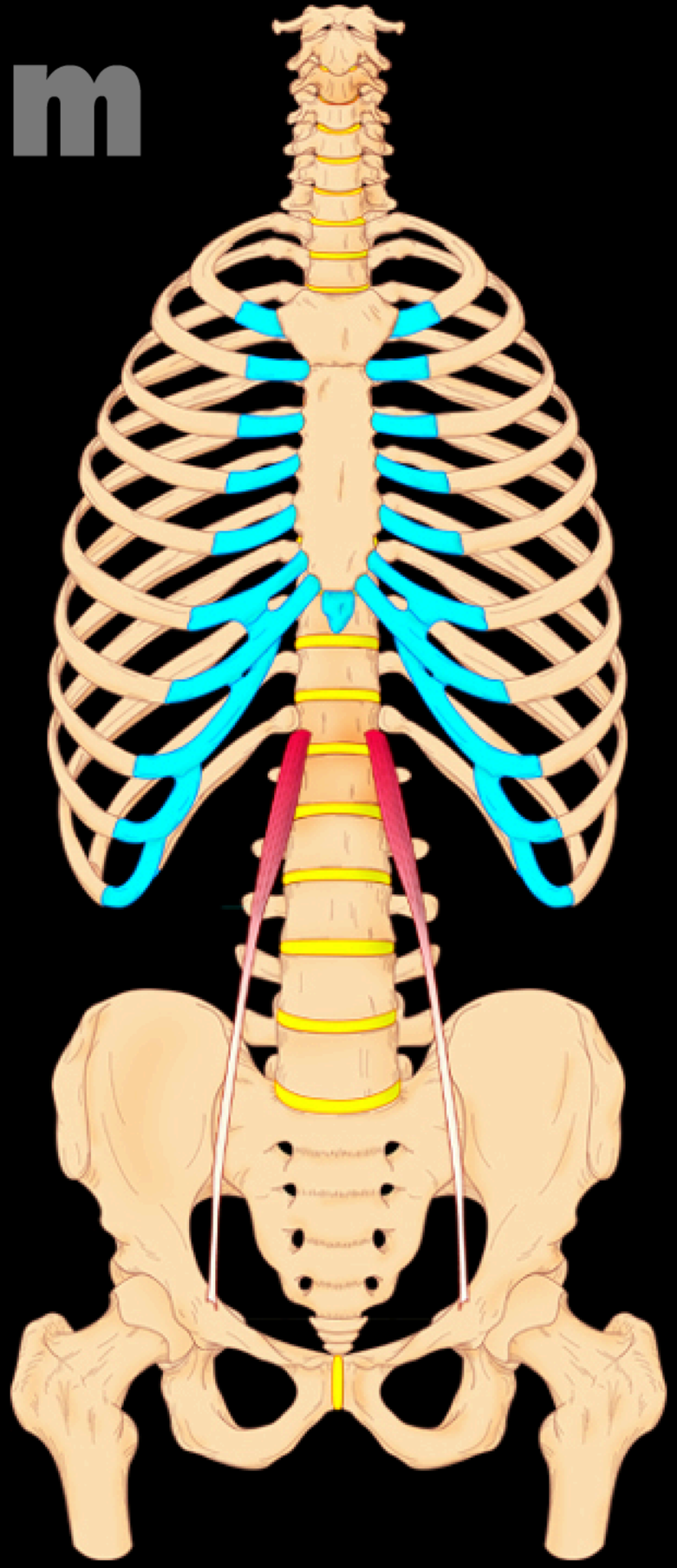

Subvertebral Musculature

Psoas major muscle

Annexed by the limb - not present

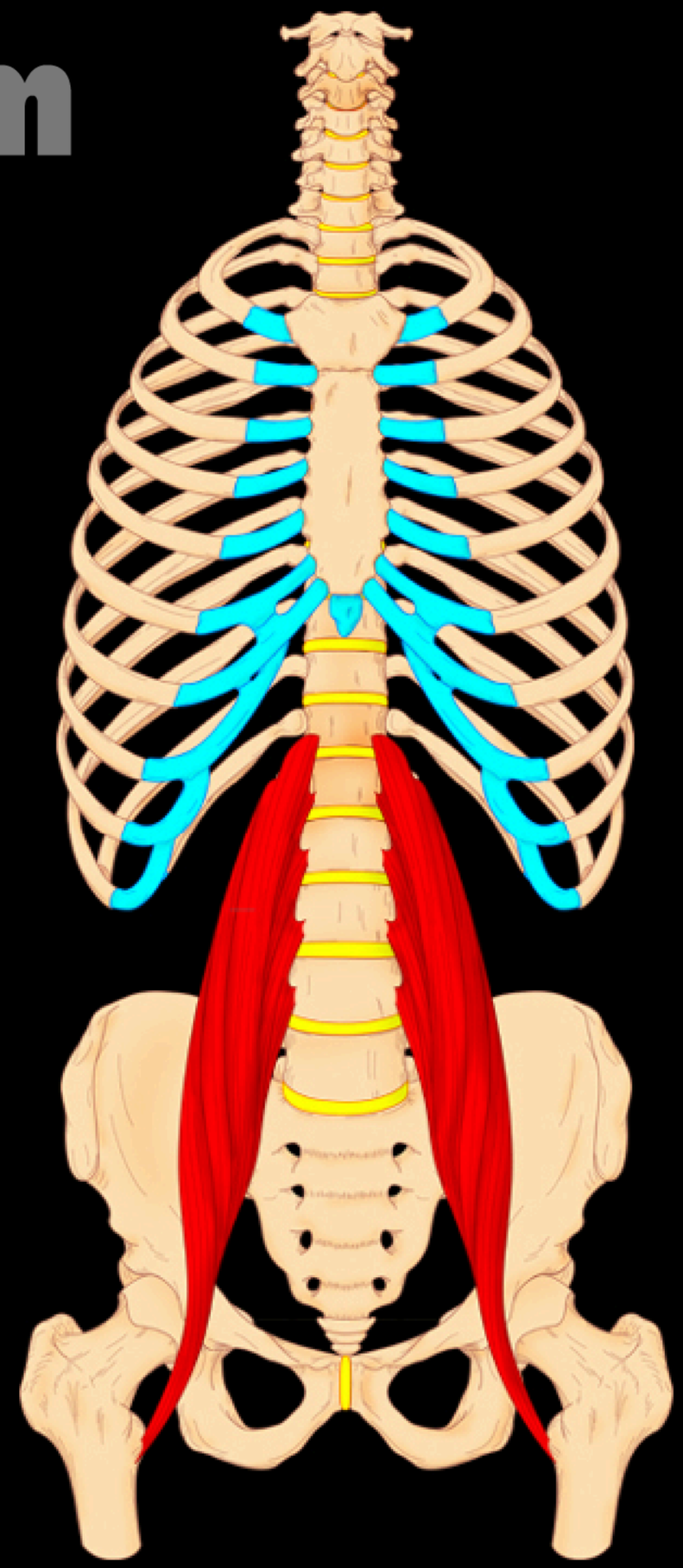

Lateral Musculature - Internal Layer

- Levator ani muscle
  - Pubococcygeus part
  - Iliococcygeus part

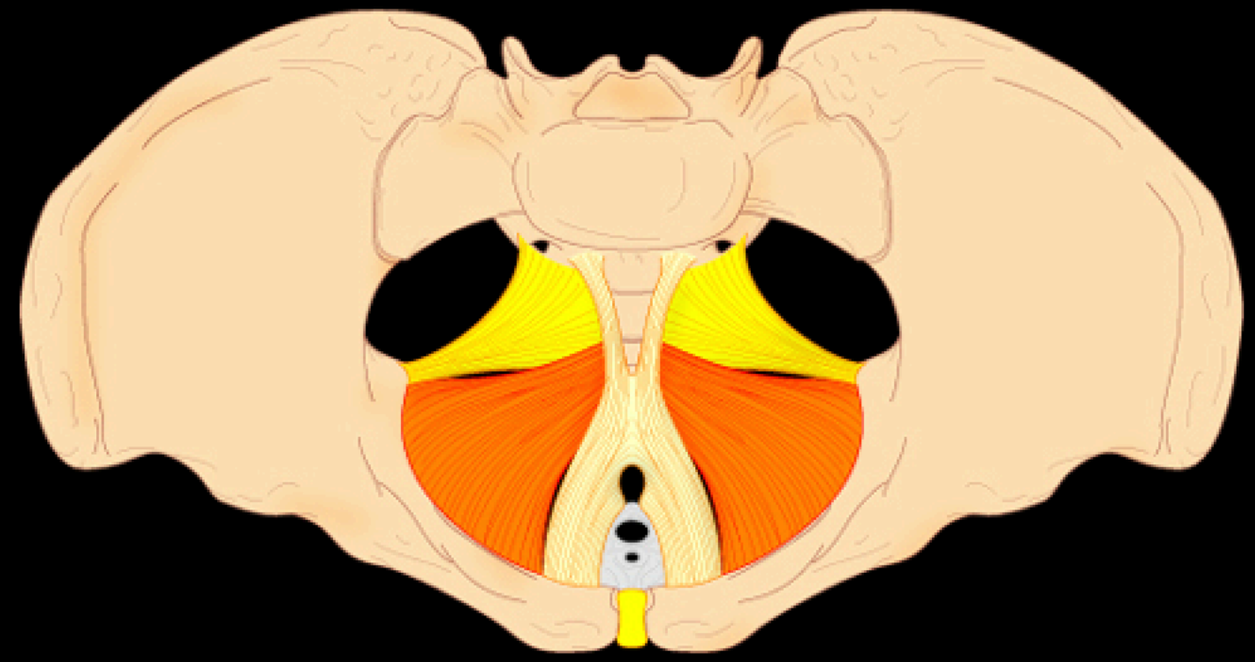

Lateral Musculature - Internal Layer

Ischiococcygeus muscle

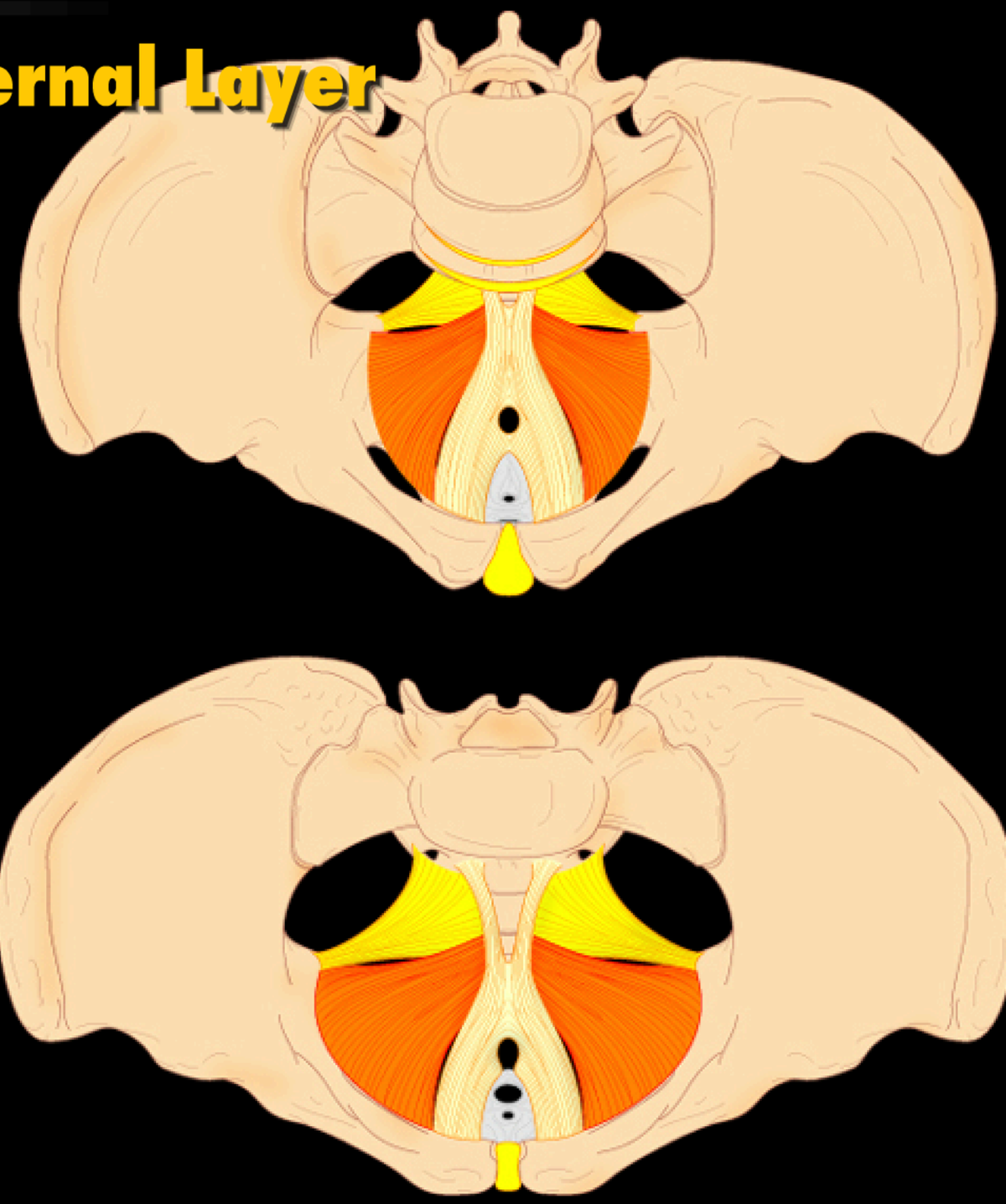

Lateral Musculature - Internal Layer

Evolutionary considerations

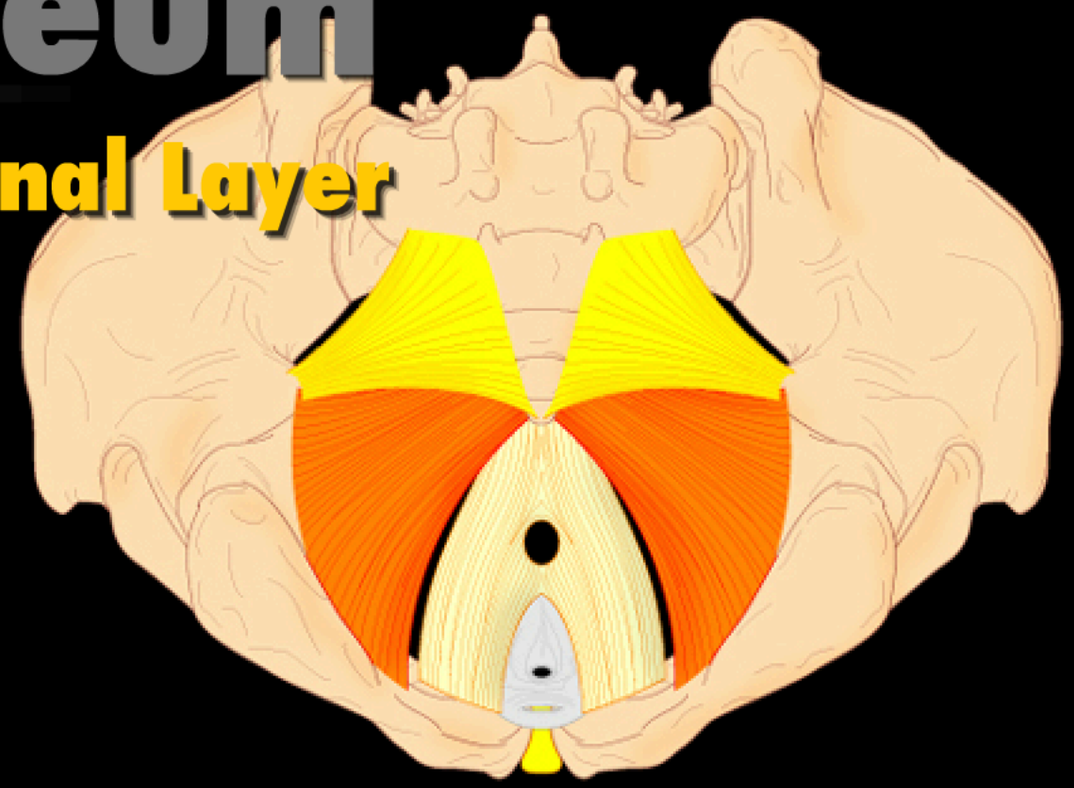

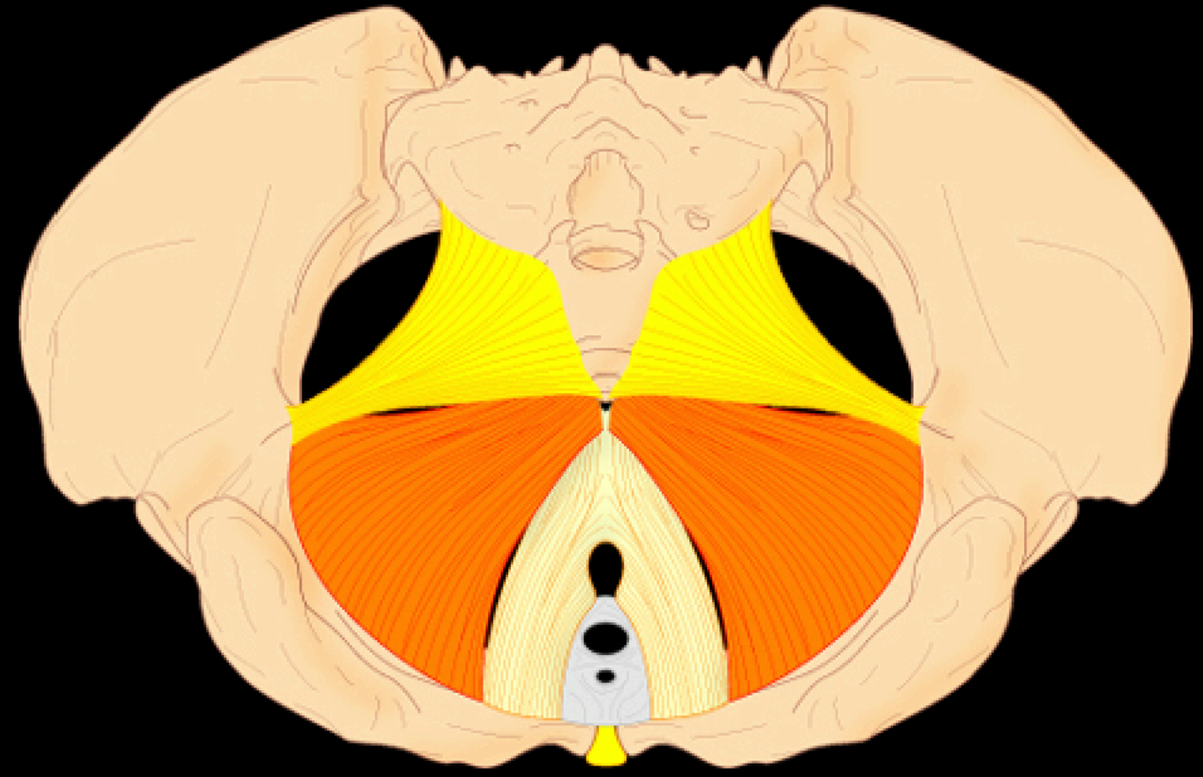

Lateral Musculature - Middle Layer

Obturator internus muscle

Annexed by the lower limb

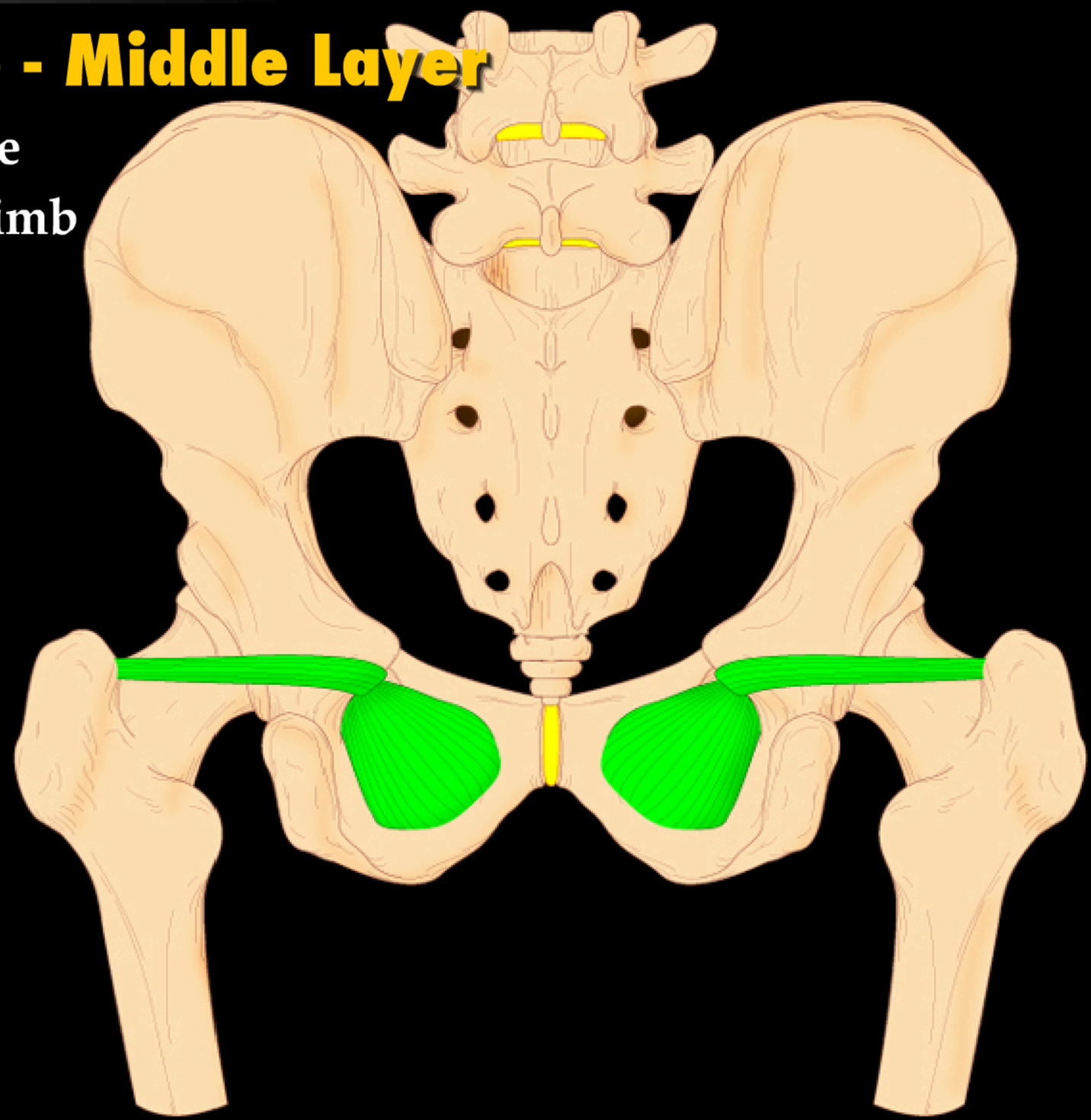

Lateral Musculature - Middle Layer

Deep external anal sphincter

Male

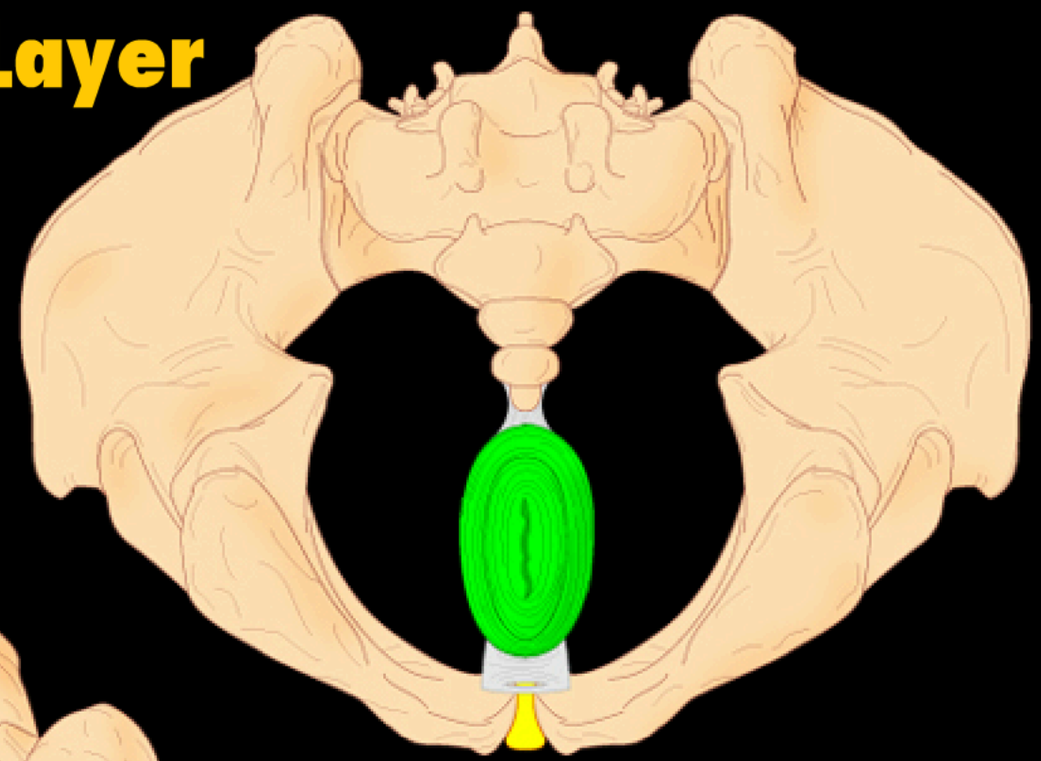

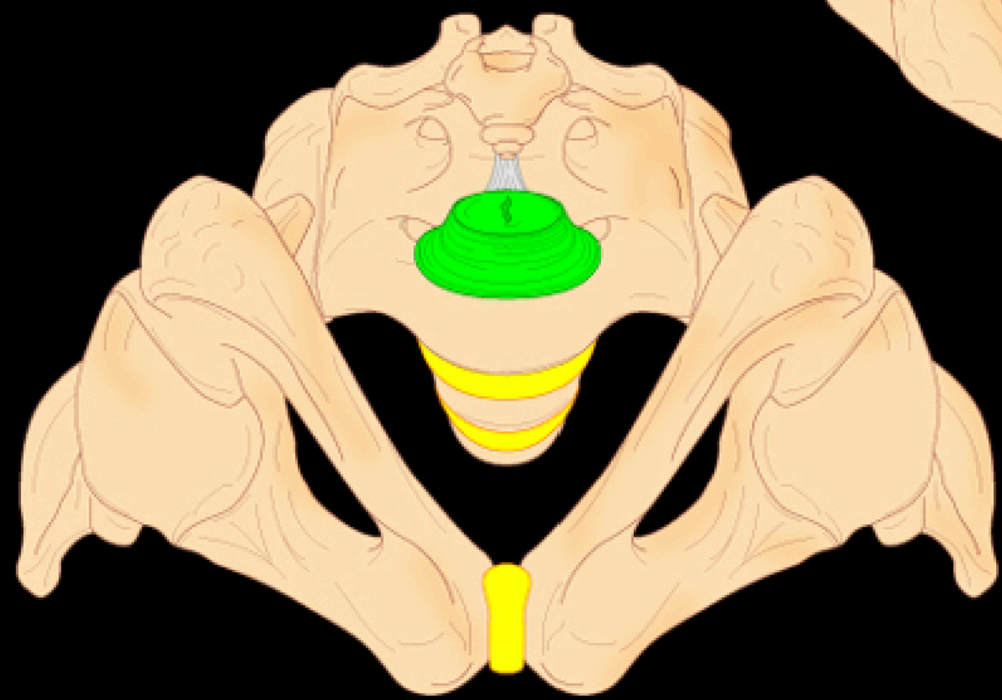

Lateral Musculature - Middle Layer

Deep external anal sphincter

Female

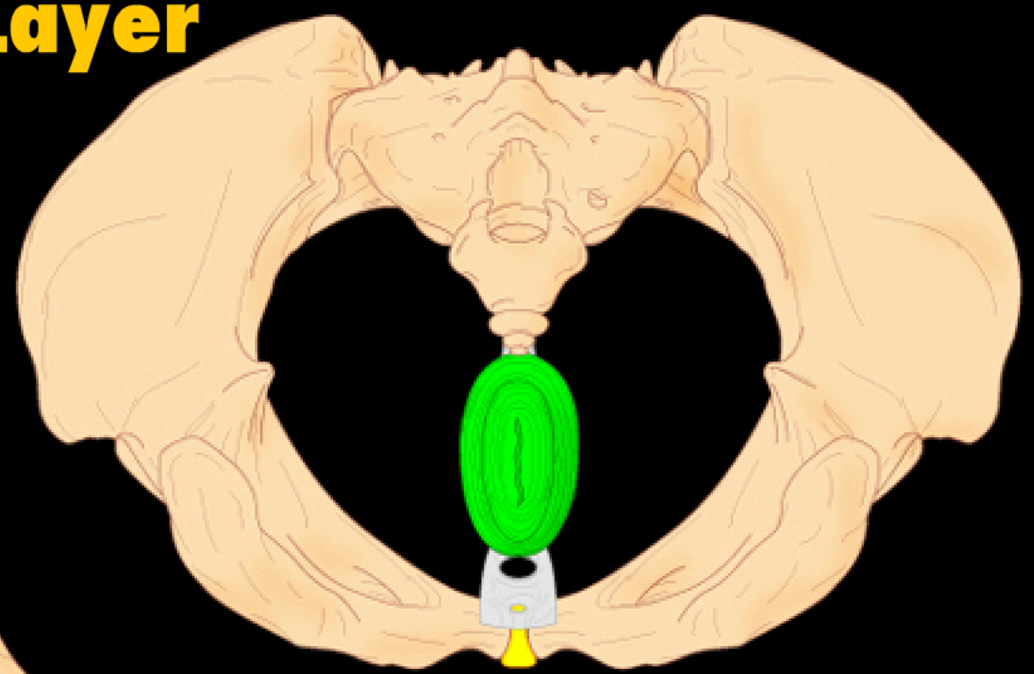

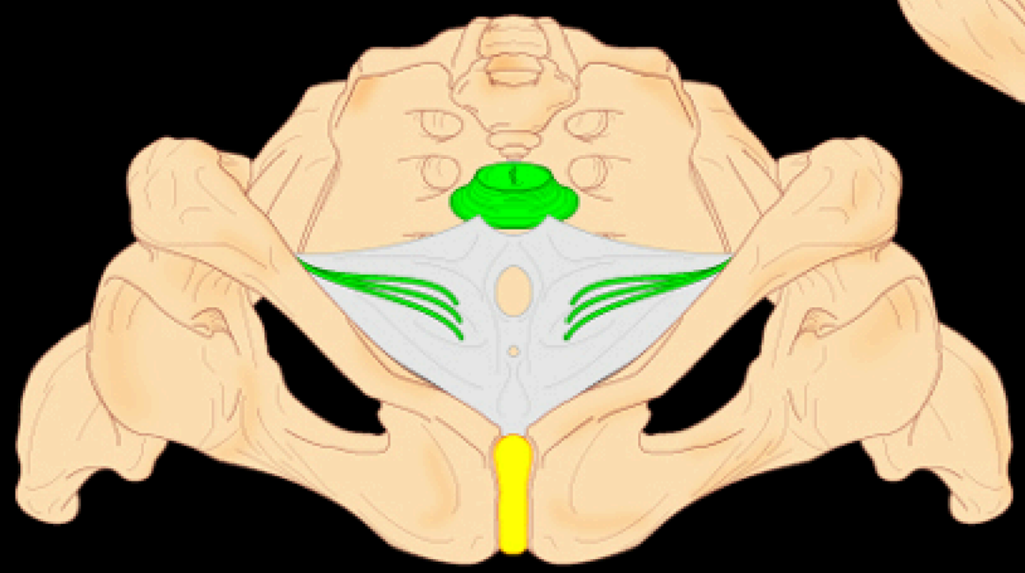

Lateral Musculature - Middle Layer

Deep transverse perinei muscle

Male

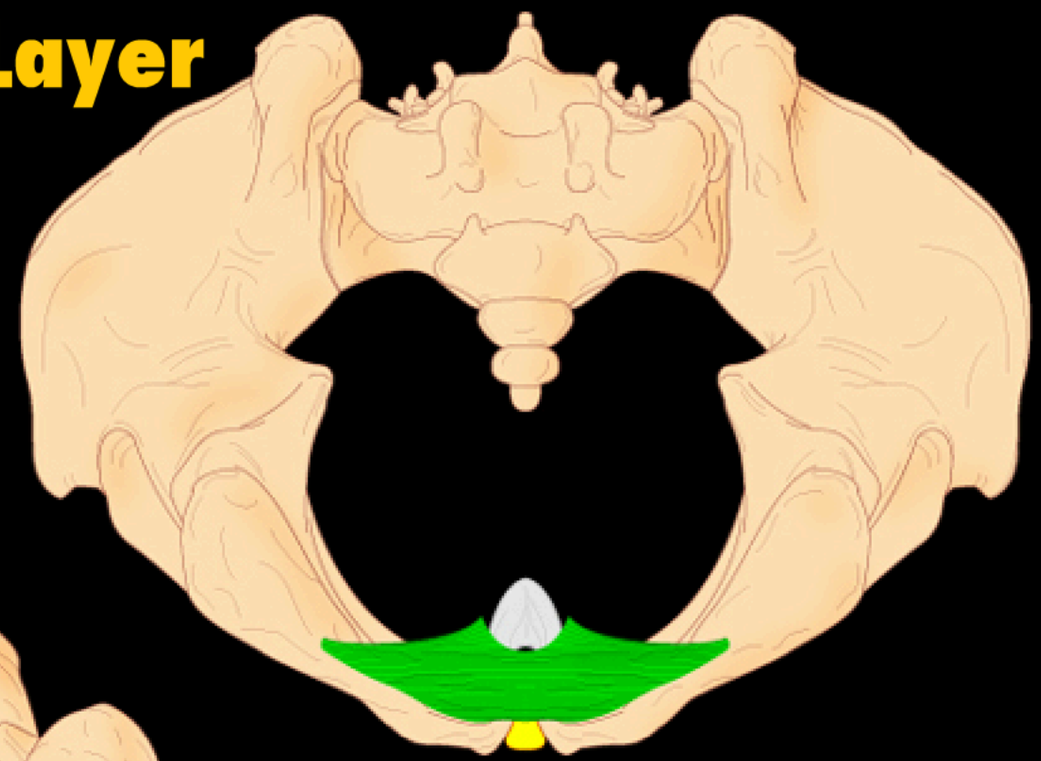

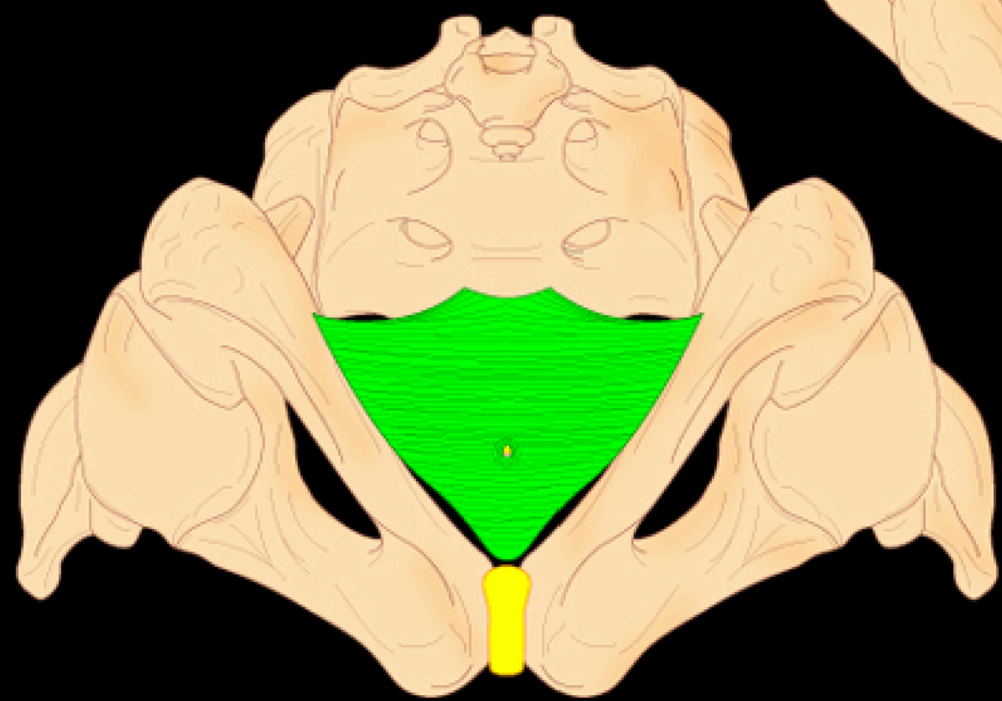

Lateral Musculature - Middle Layer

External urethral sphincter muscle

Male

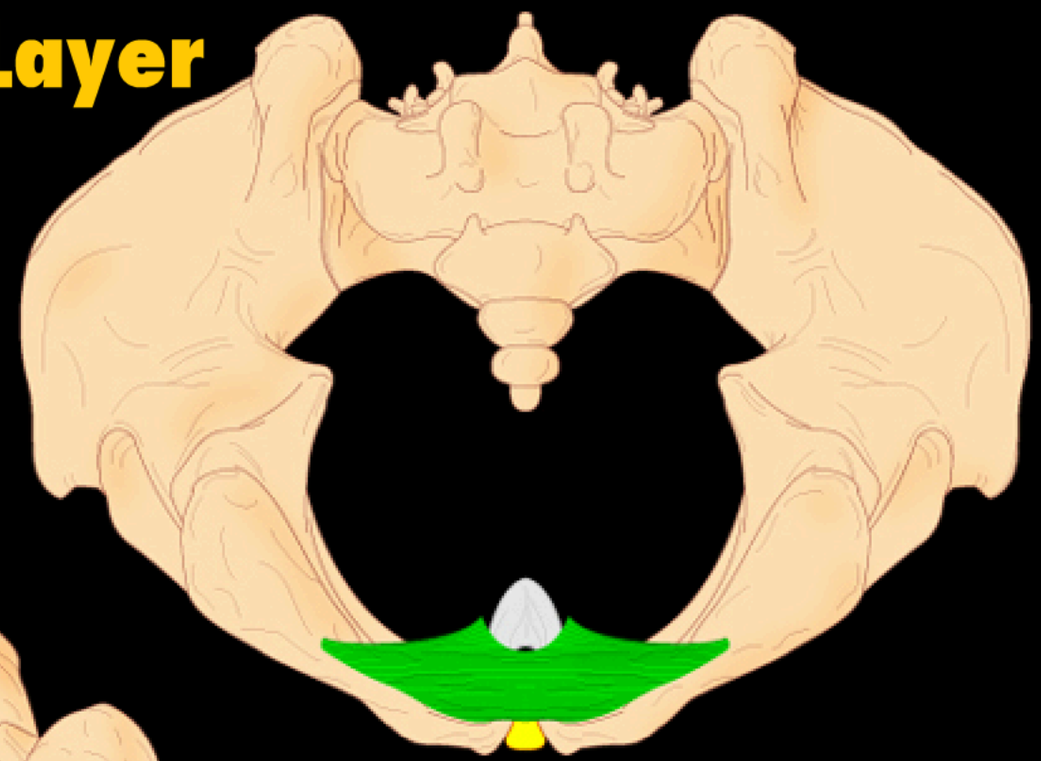

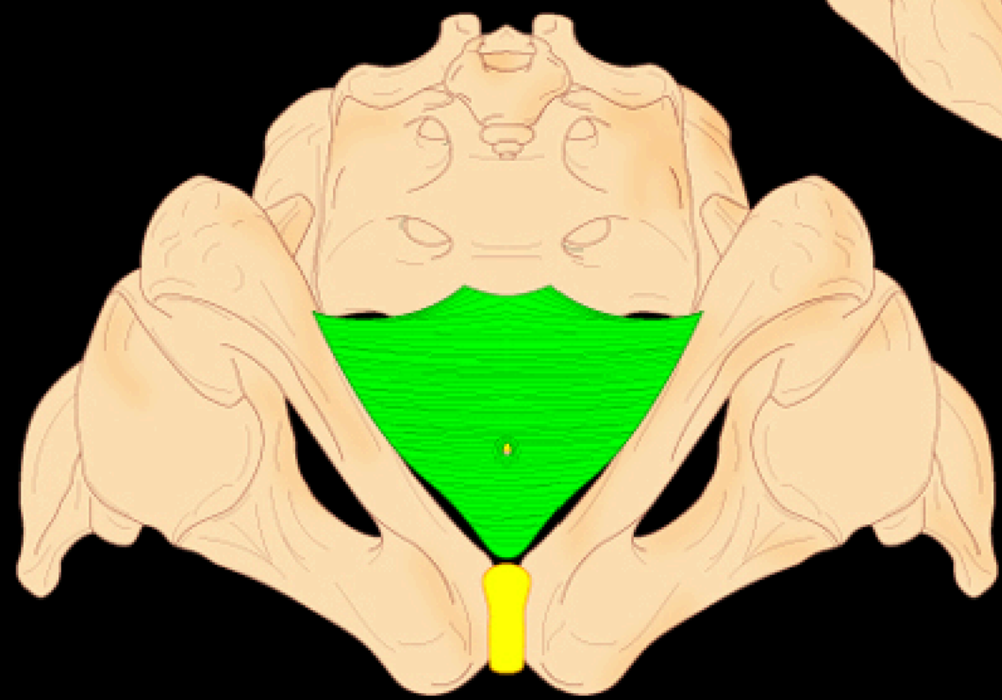

Lateral Musculature - Middle Layer

Sphincter urethrovaginalis muscle

Female

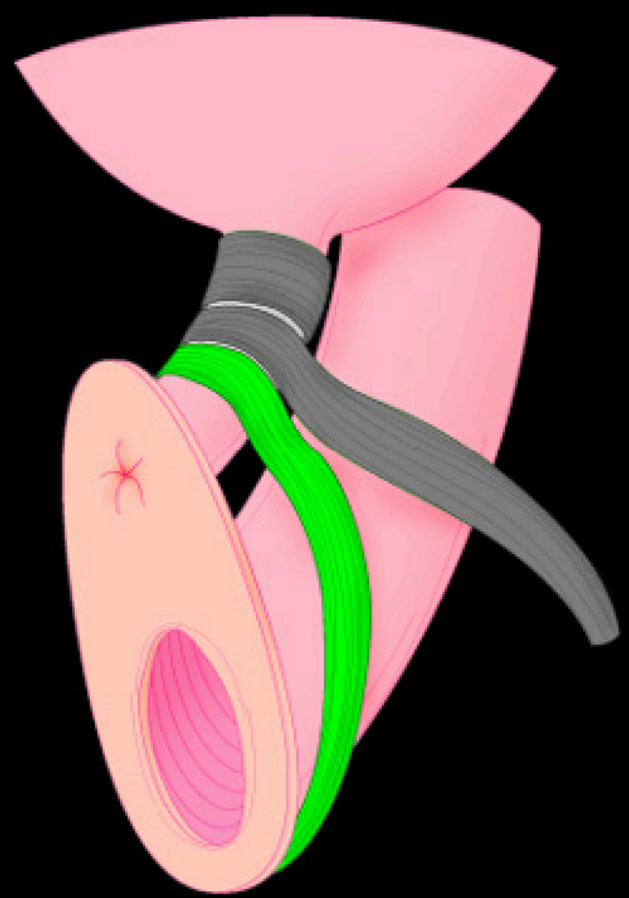

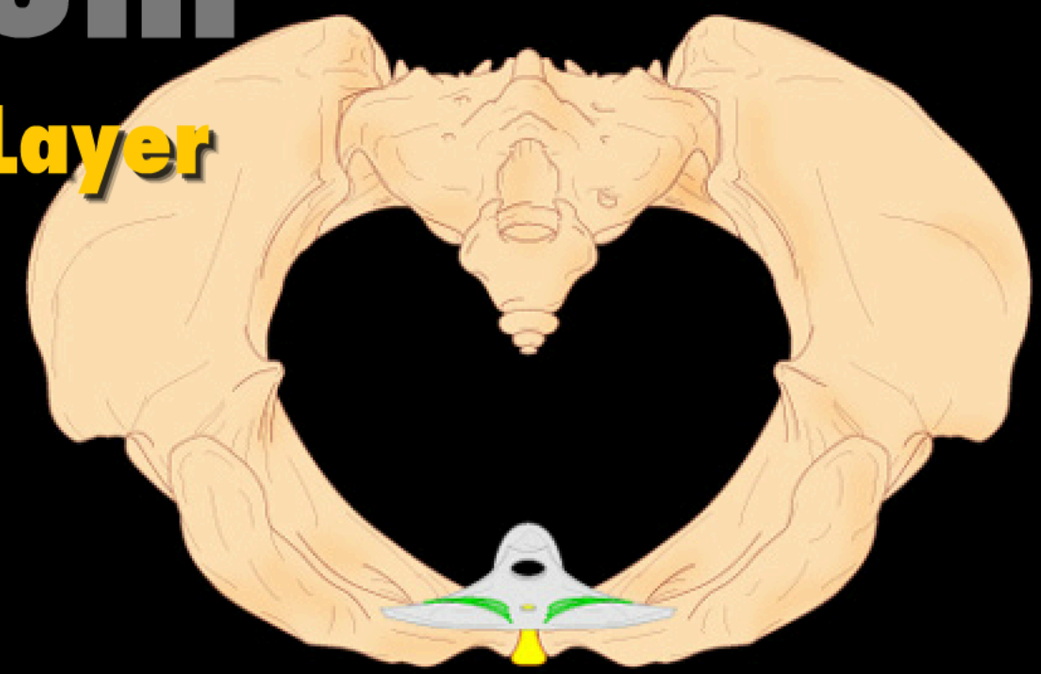

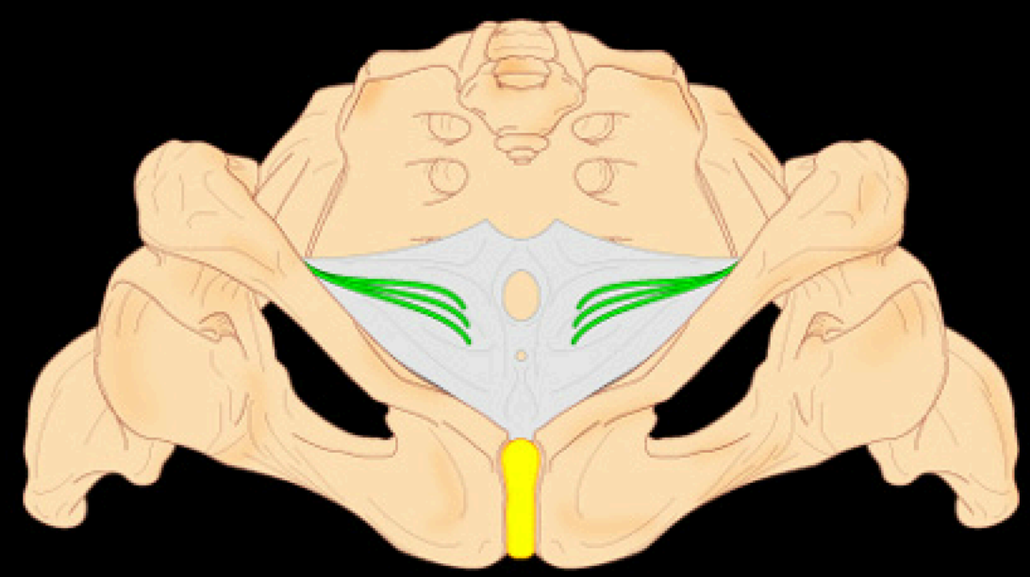

Lateral Musculature - Middle Layer

Compressor urethrae muscle

Female

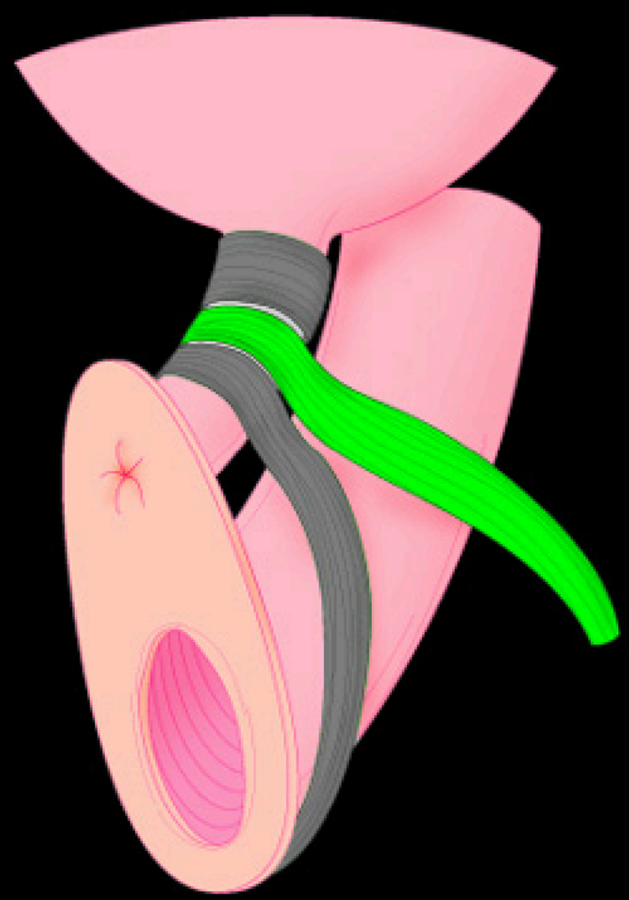

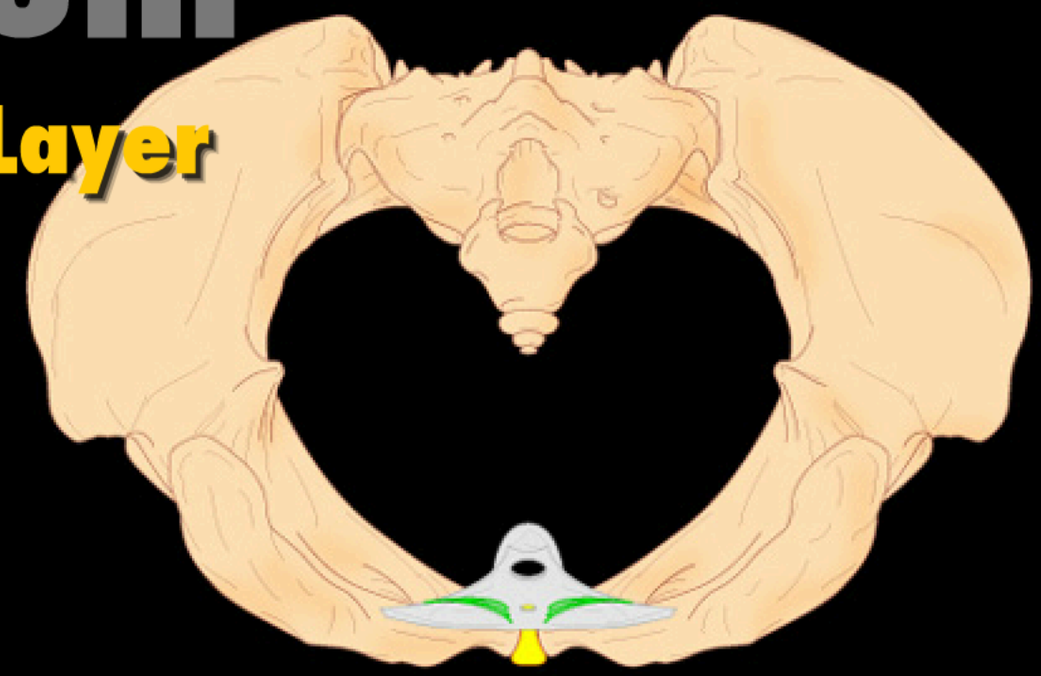

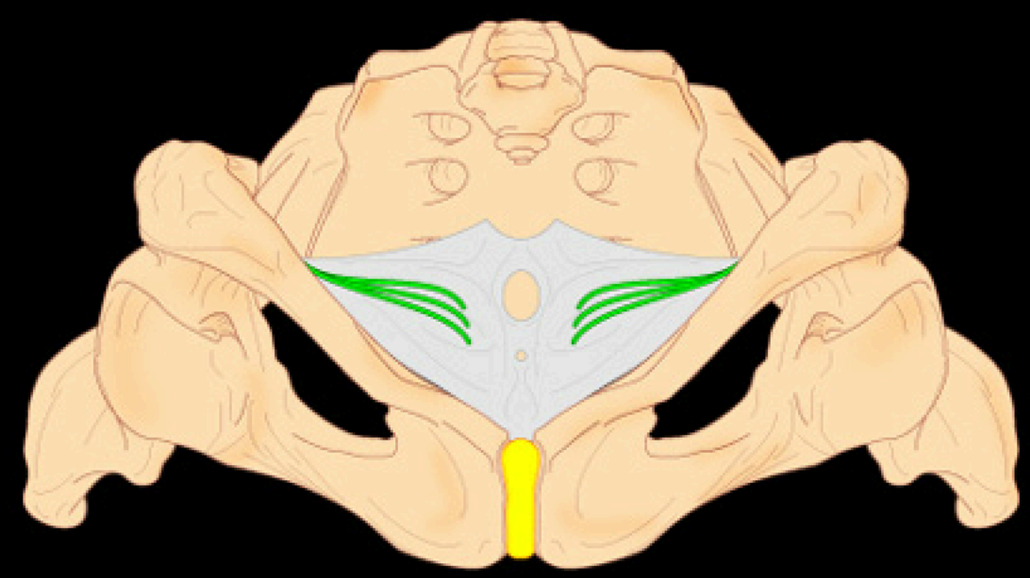

Lateral Musculature - Middle Layer

External urethral sphincter muscle

Female

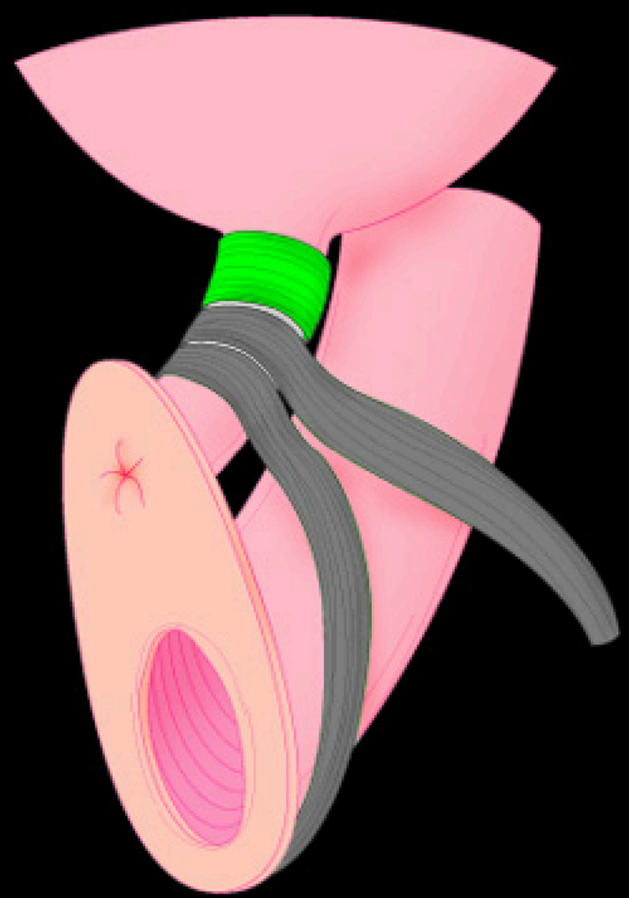

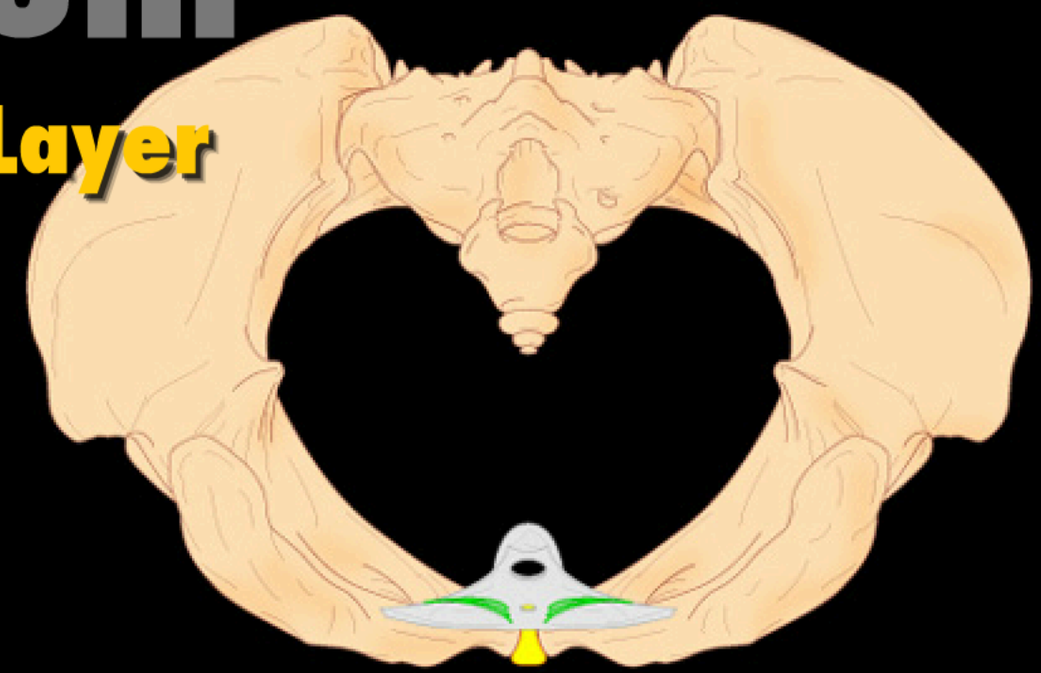

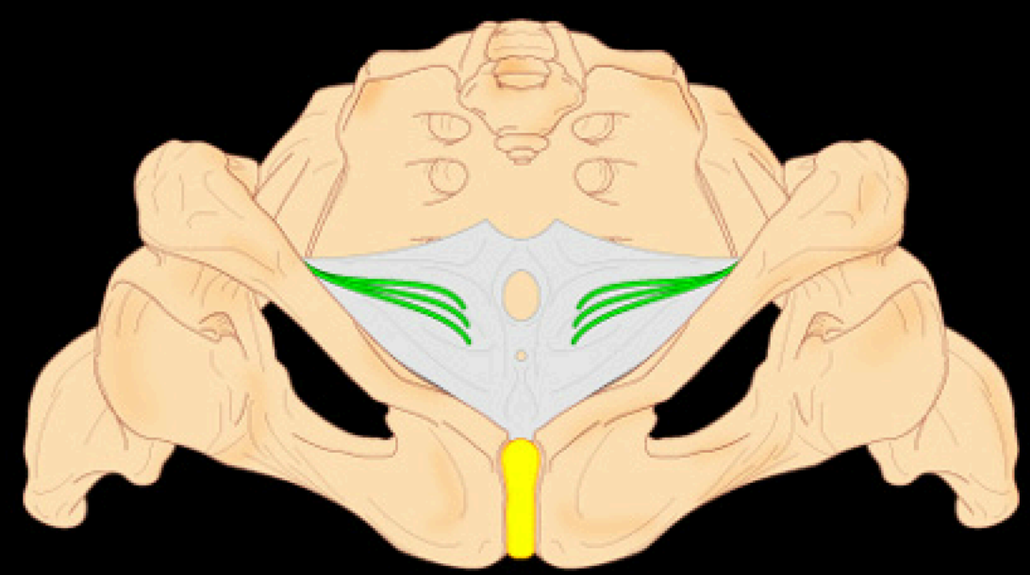

Lateral Musculature - Middle Layer

Summary of male muscles

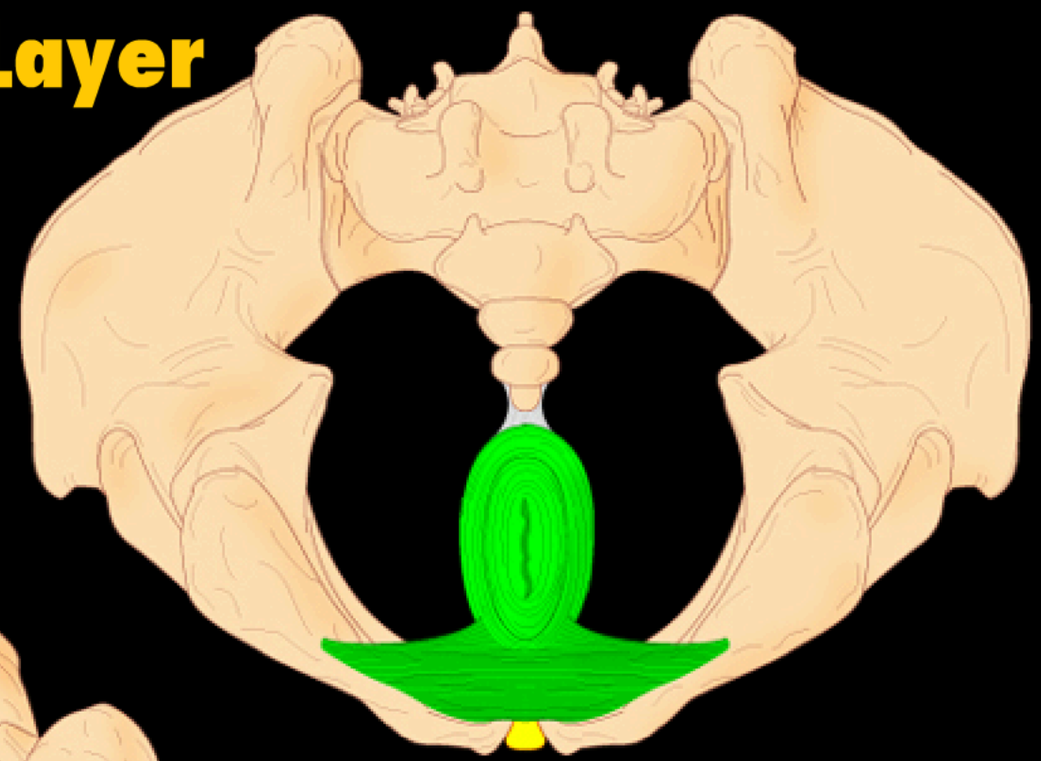

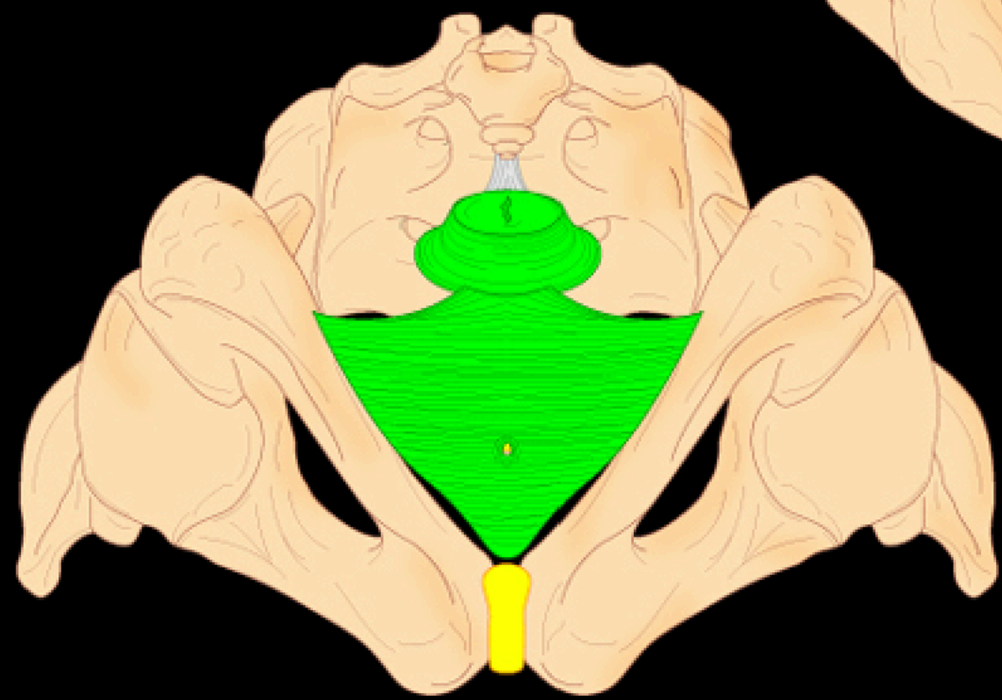

Lateral Musculature - Middle Layer

Summary of female muscles

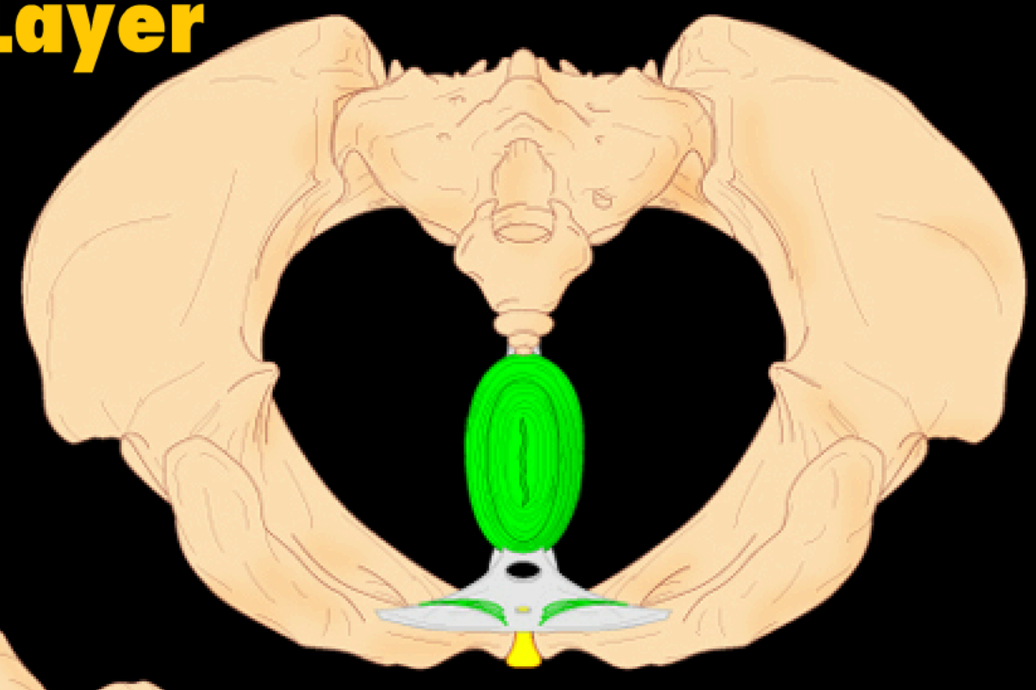

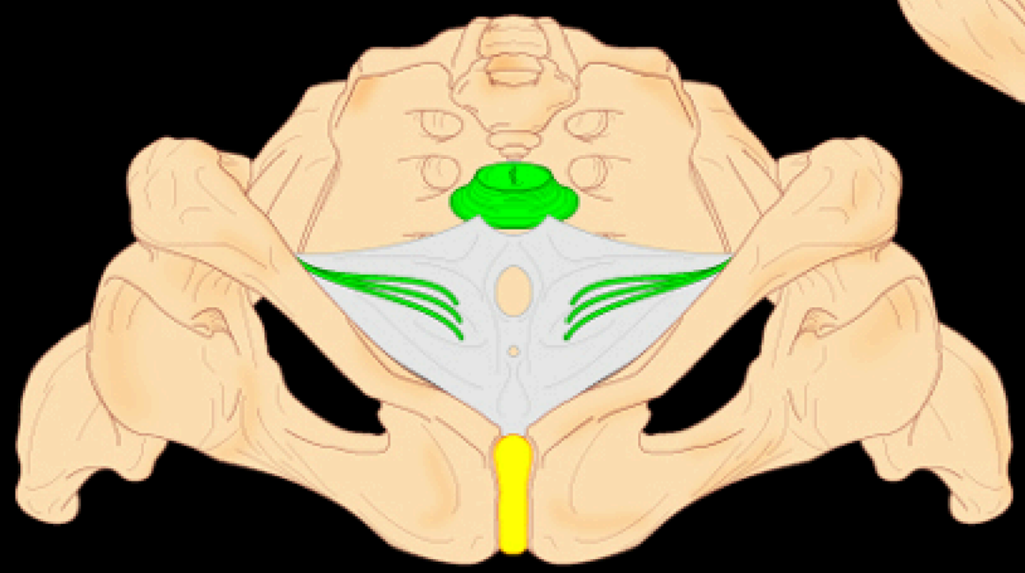

Lateral Musculature - External Layer

Obturator externus muscle

Annexed by the lower limb

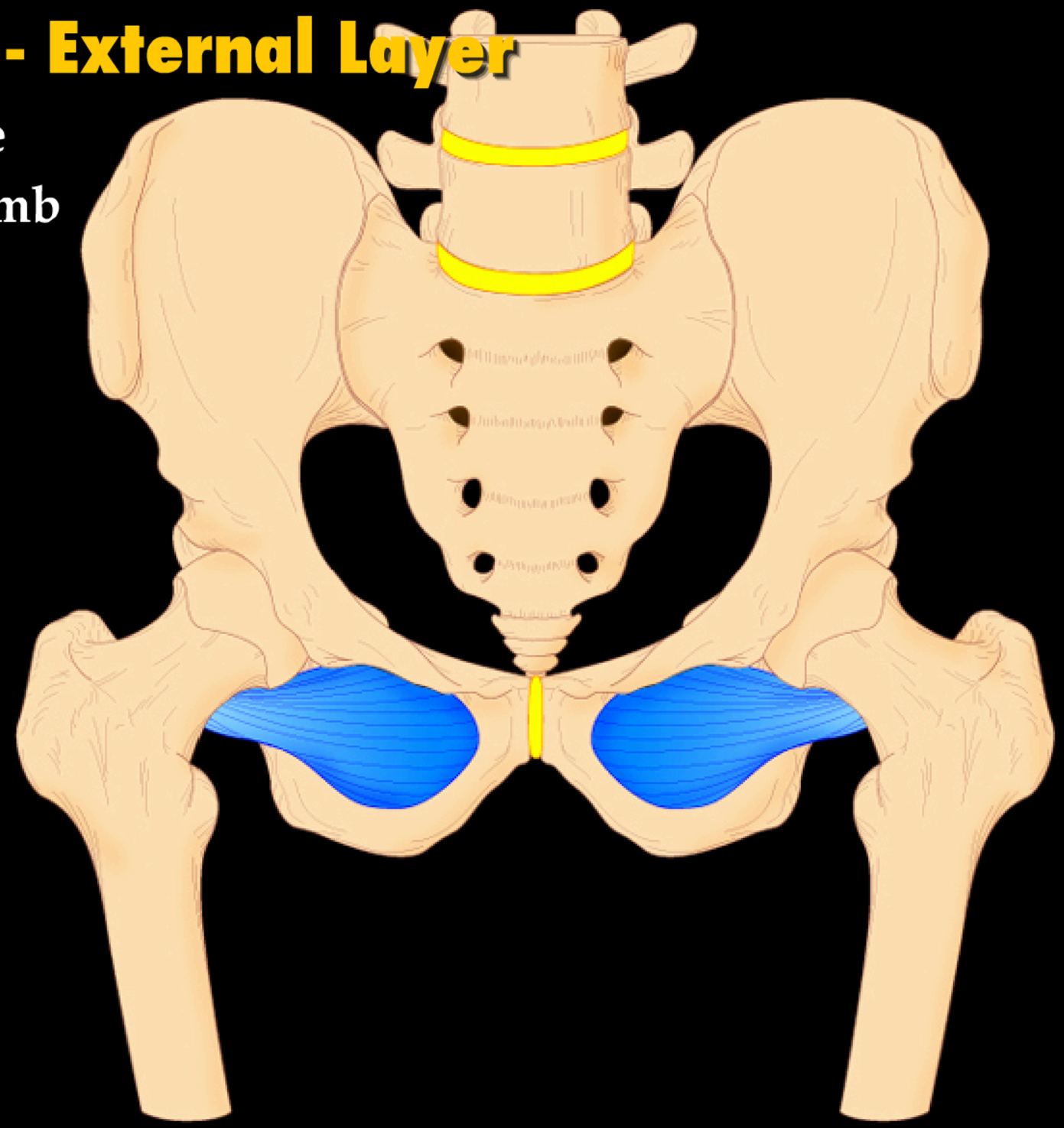

Lateral Musculature - External Layer

Superficial external anal sphincter

Male

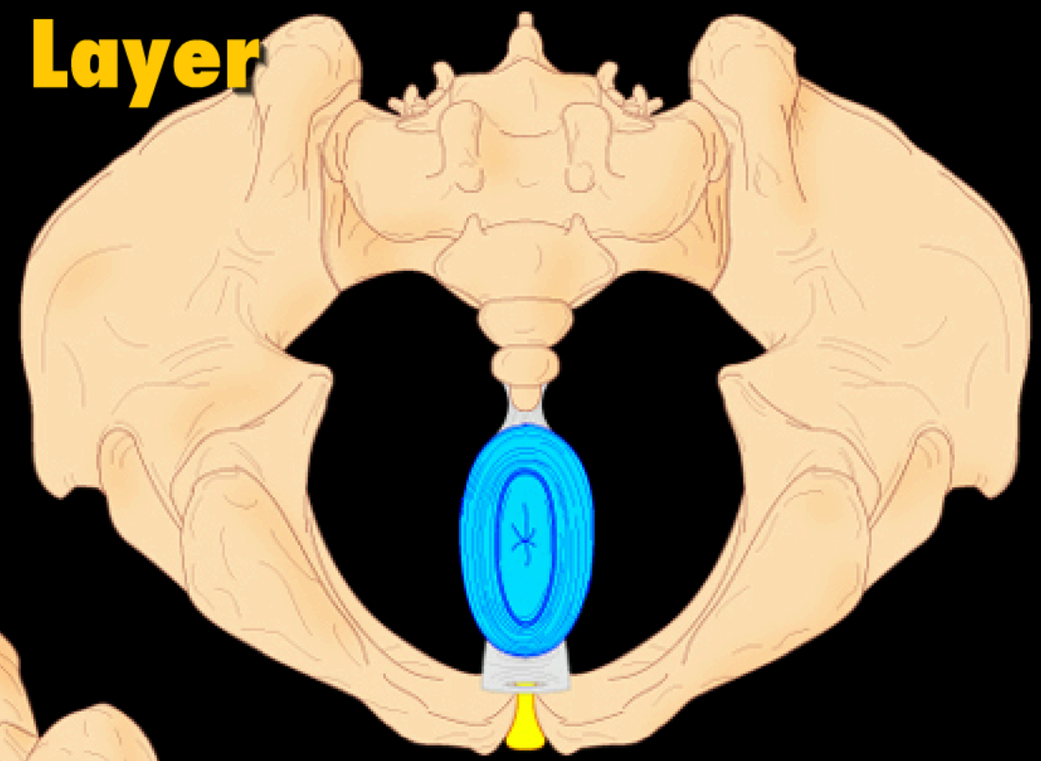

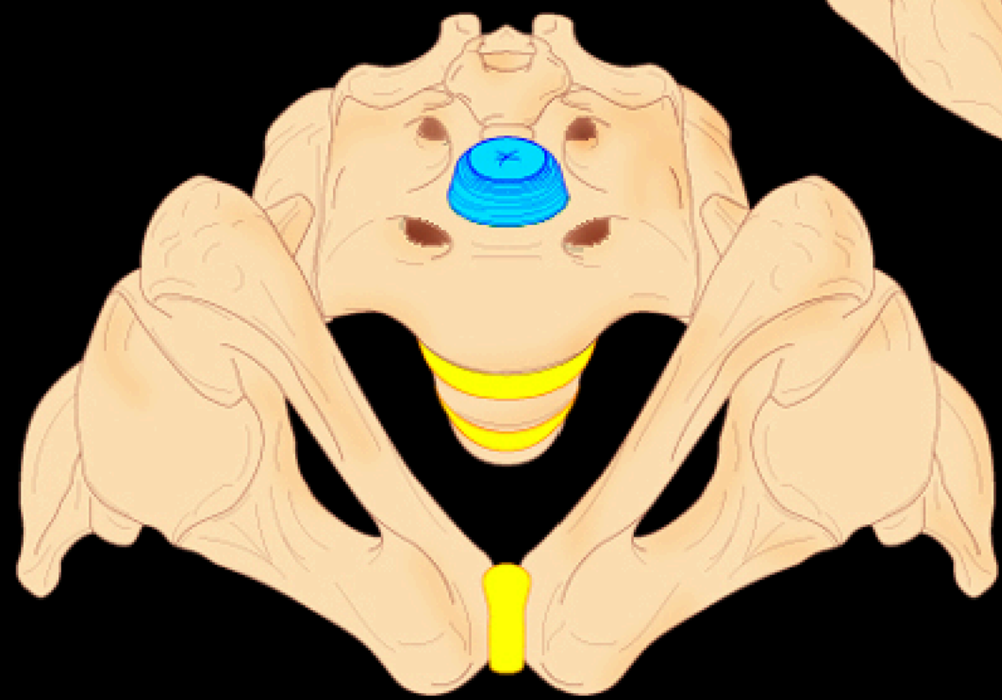

Lateral Musculature - External Layer

Superficial external anal sphincter

Female

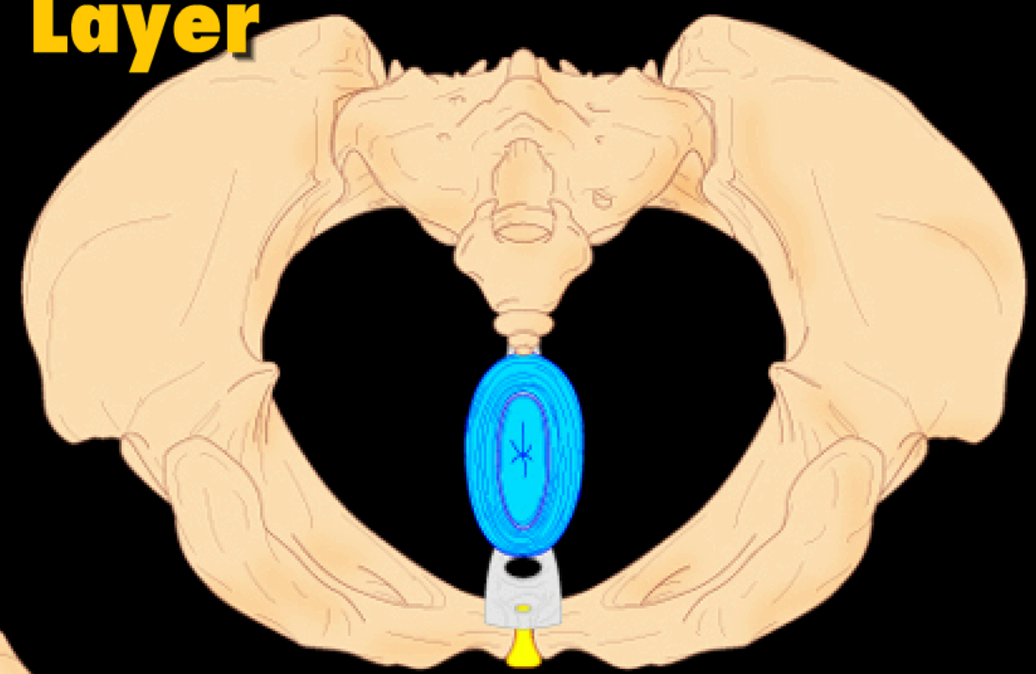

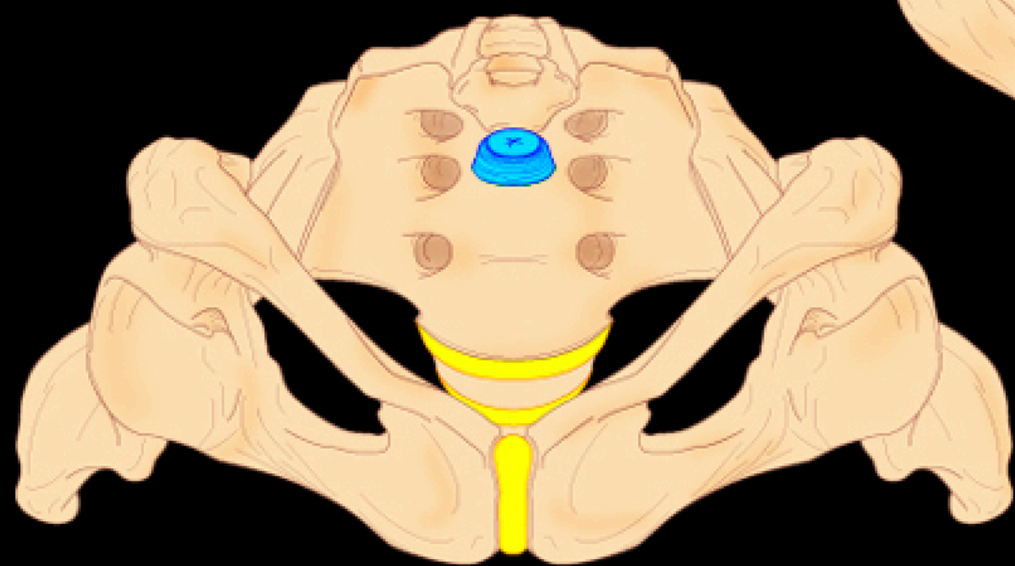

Lateral Musculature - External Layer

Superficial transverse perinei muscle
Ischiocavernosus muscle
Bulbospongiosus muscle
Male



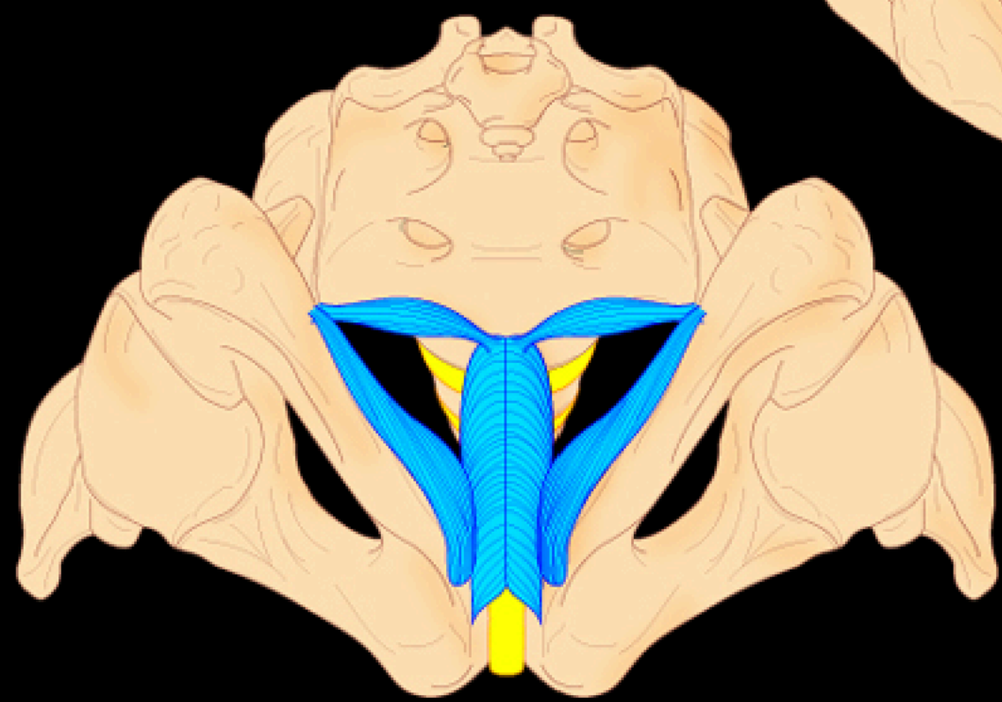

Lateral Musculature - External Layer

Superficial transverse perinei muscle
Ischiocavernosus muscle
Bulbospongiosus muscle
  Female

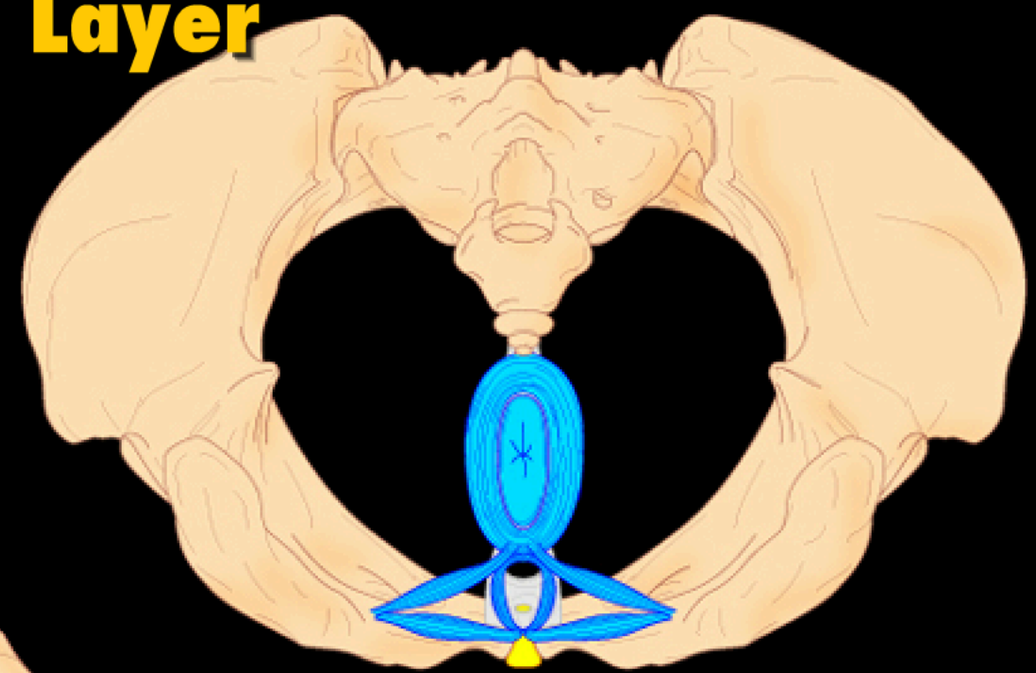

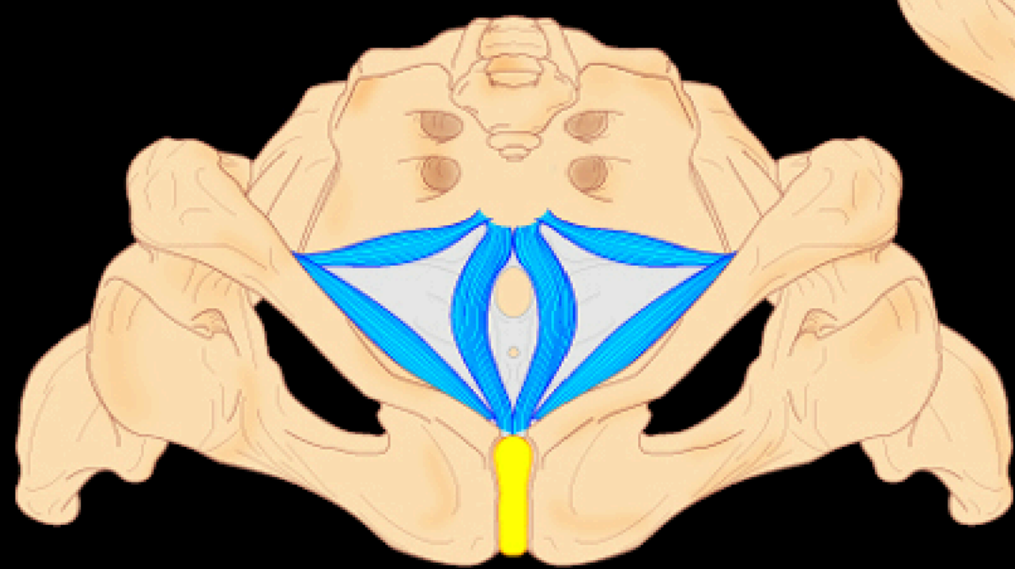

Lateral Musculature - External Layer

Summary of male muscles

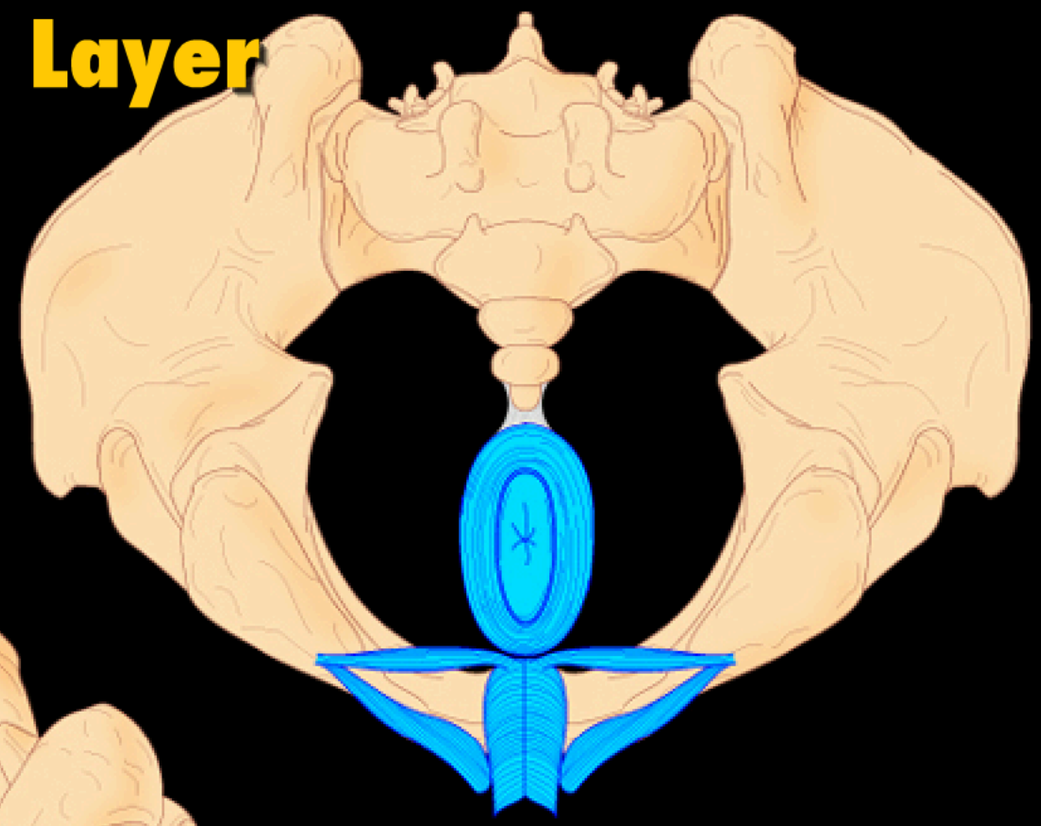

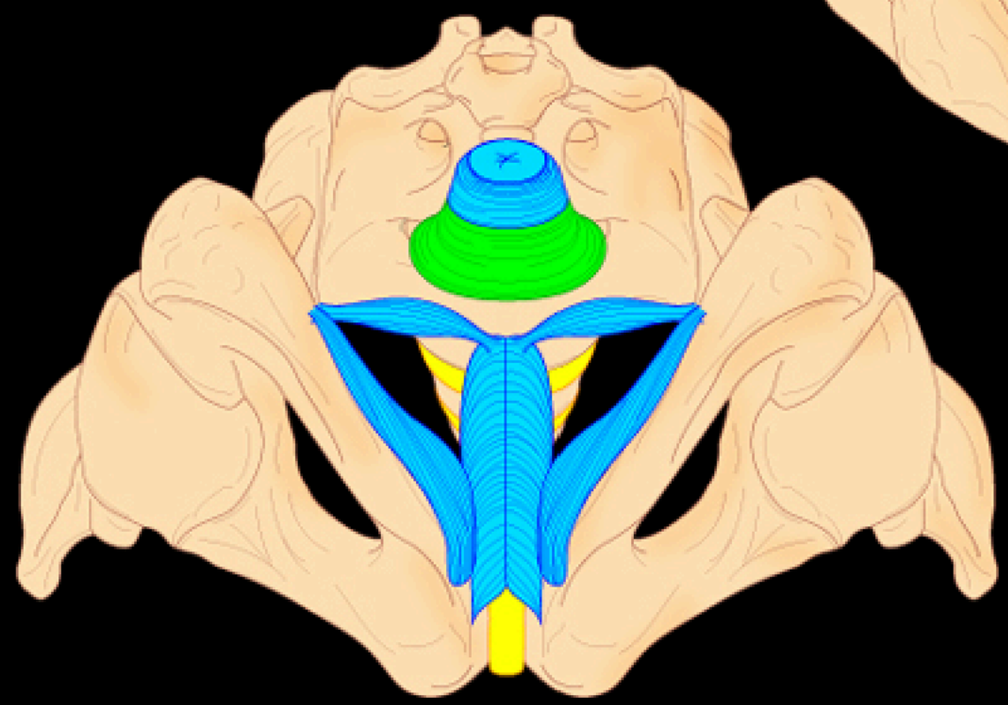

Lateral Musculature - External Layer

Summary of female muscles

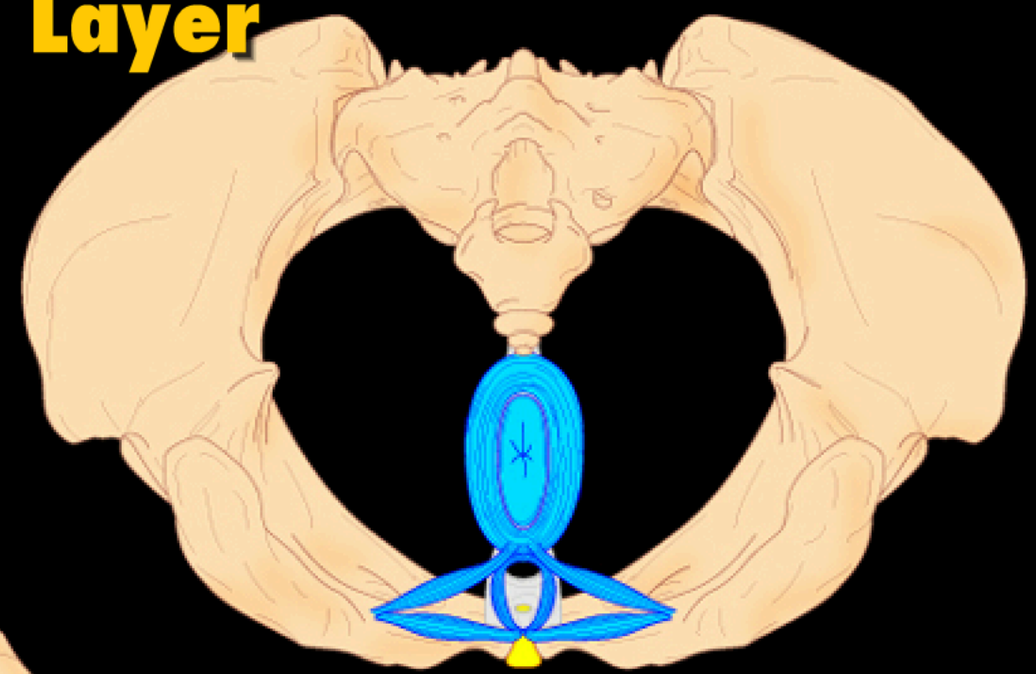

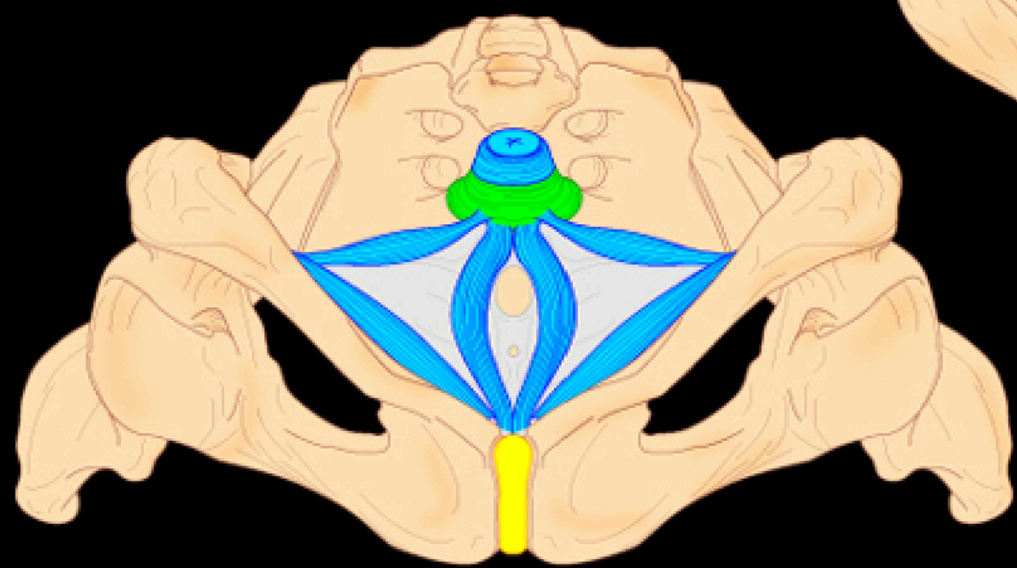

Summary of Lateral Muscles

Perineal body

Male

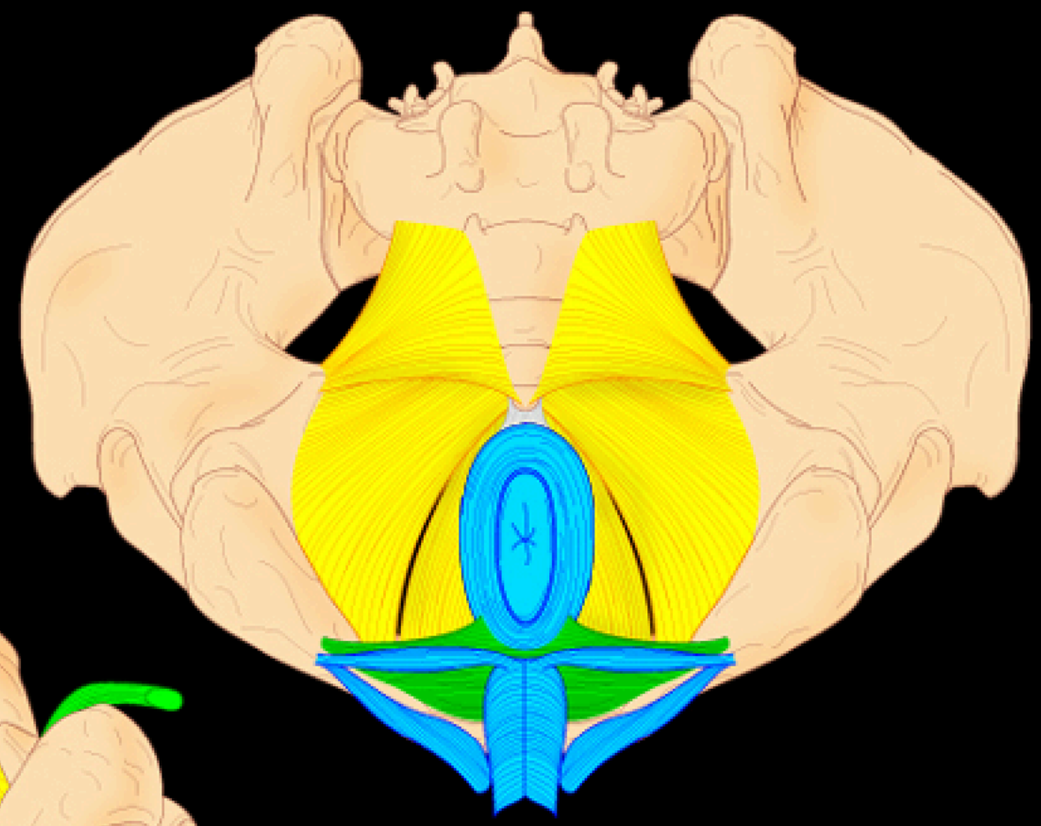

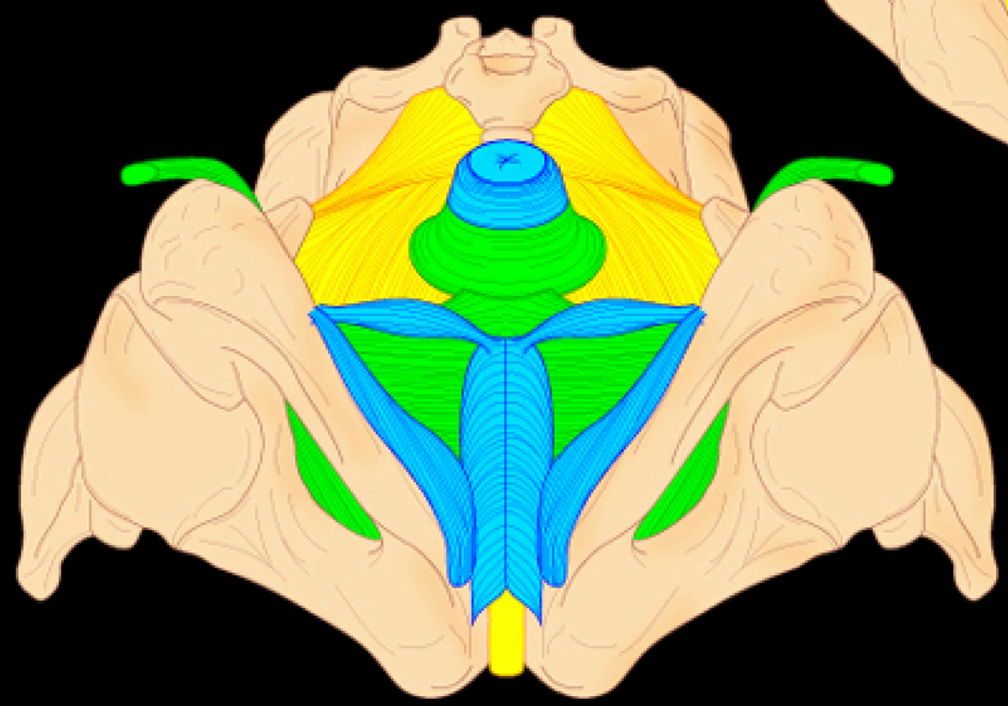

Summary of Lateral Muscles

Perineal body

Female

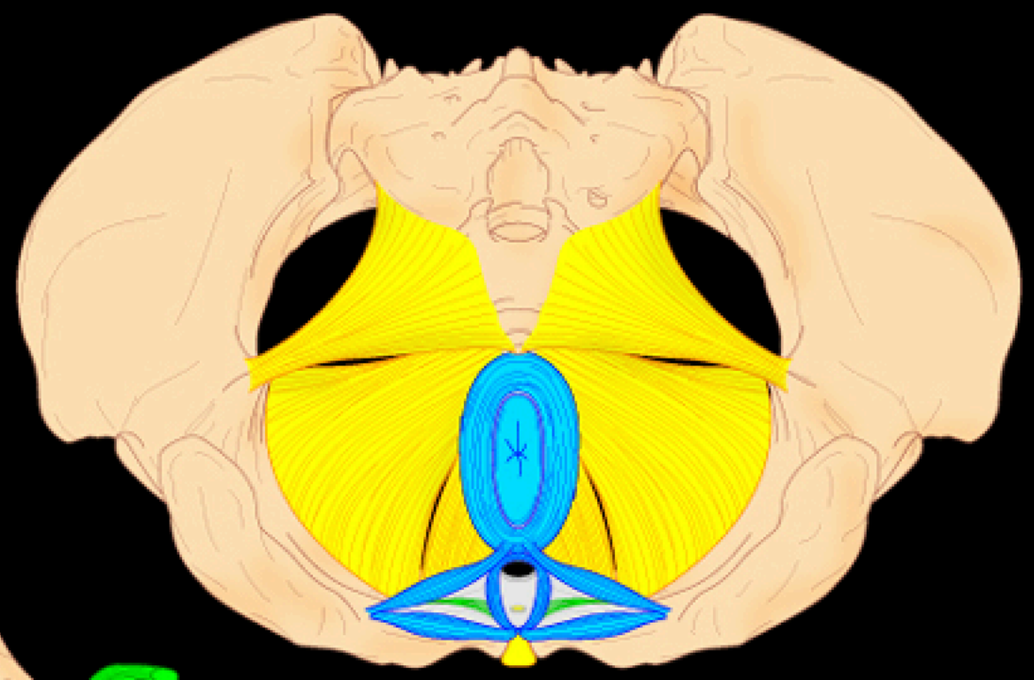

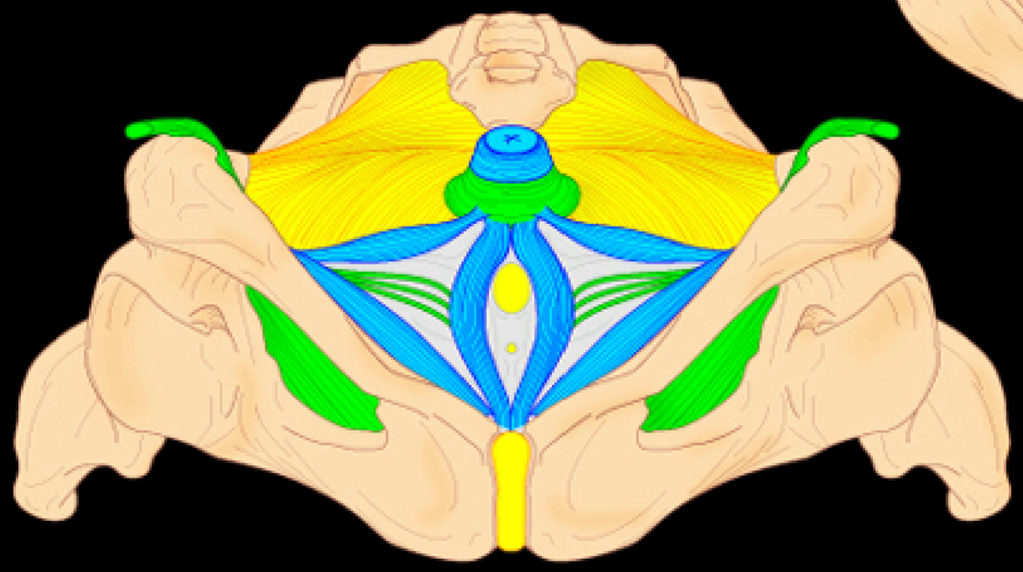

Pelvis/Perineum

Pelvic Frontal Sections

Reviewing the Anatomy

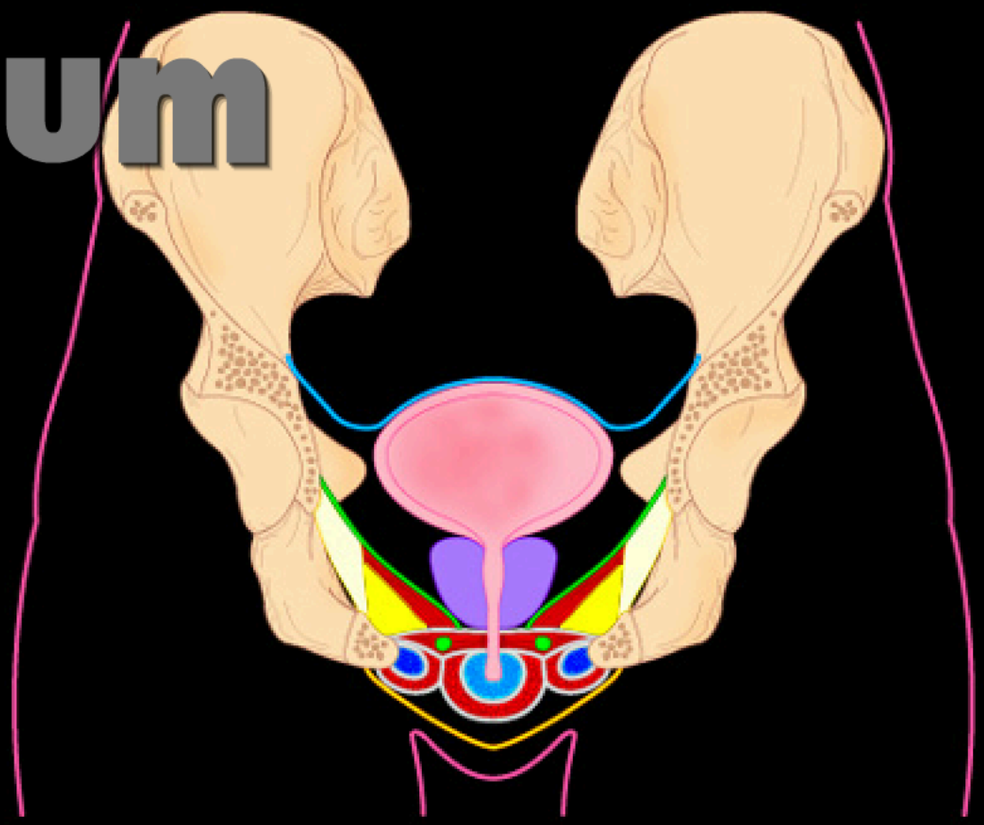

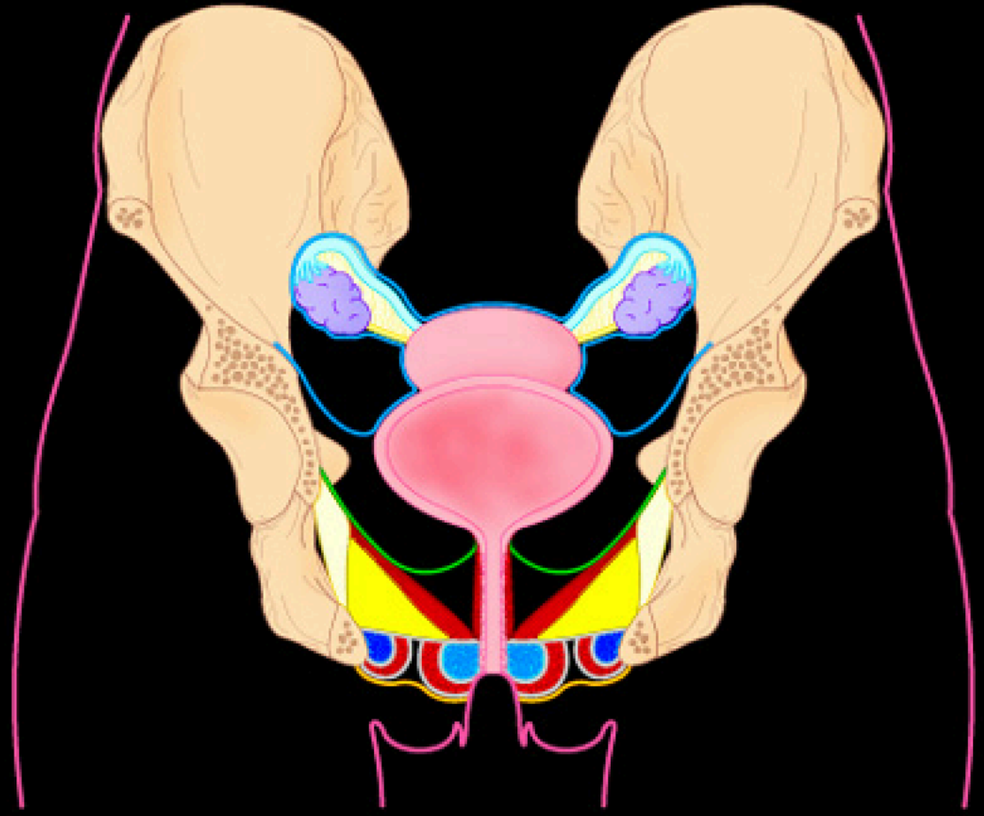

Pelvis/Perineum

Pelvic Cavity

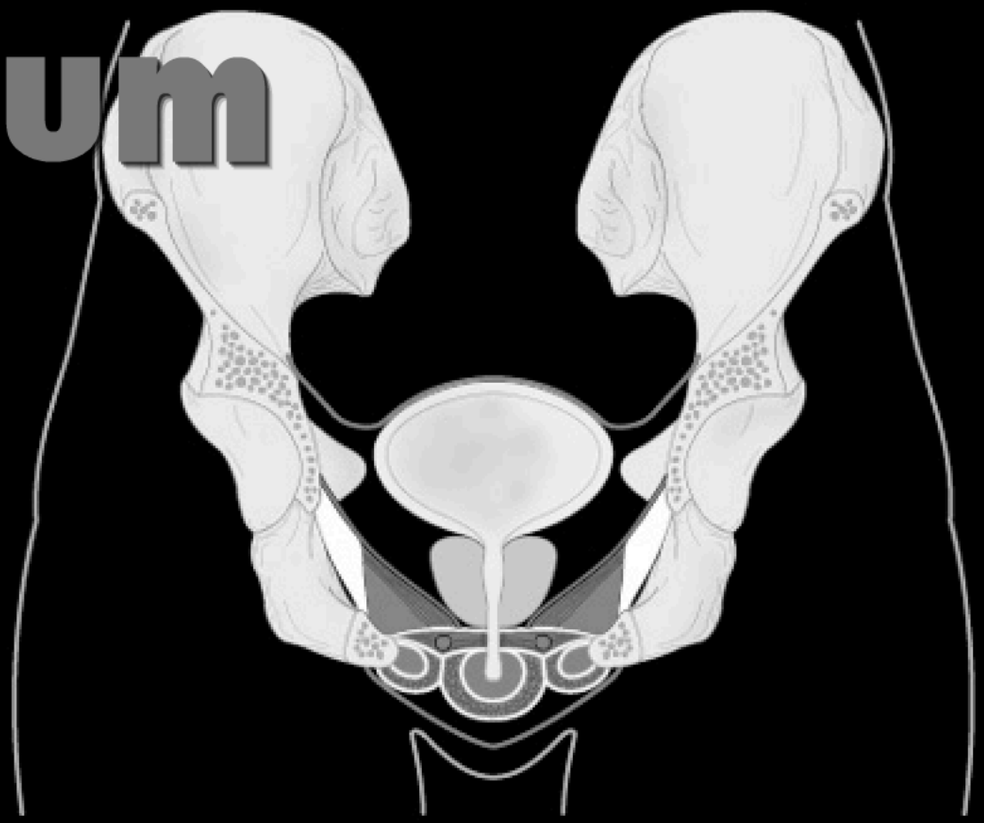

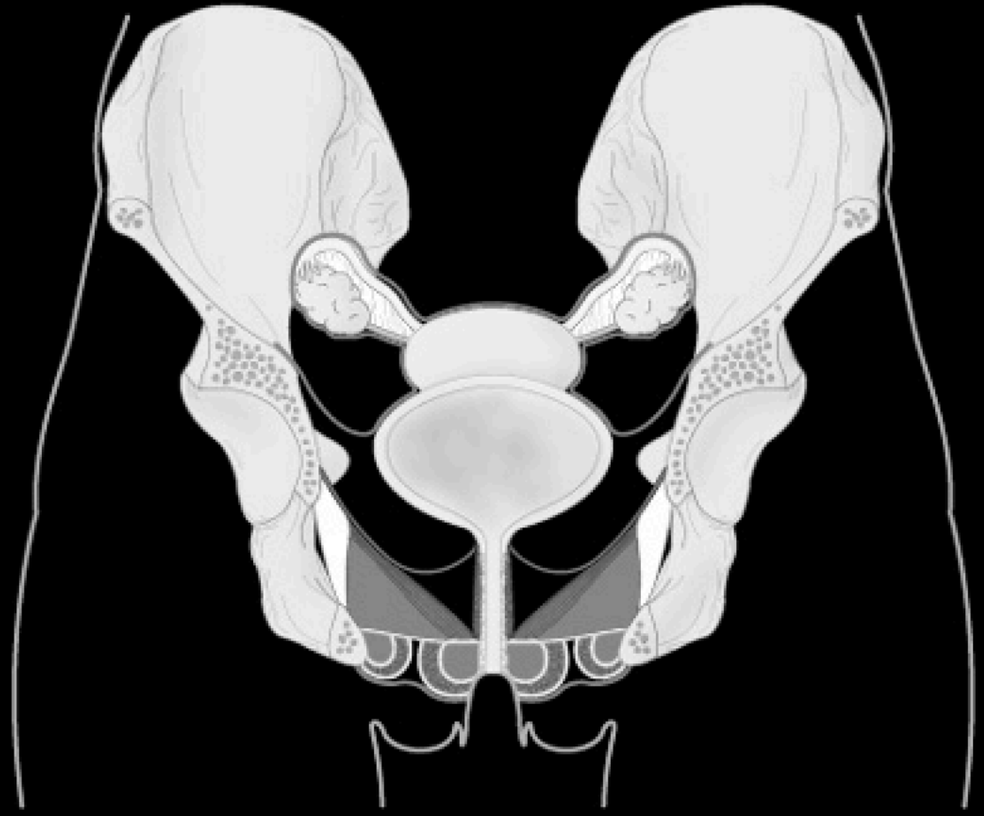

Pelvic Cavity

Boundaries

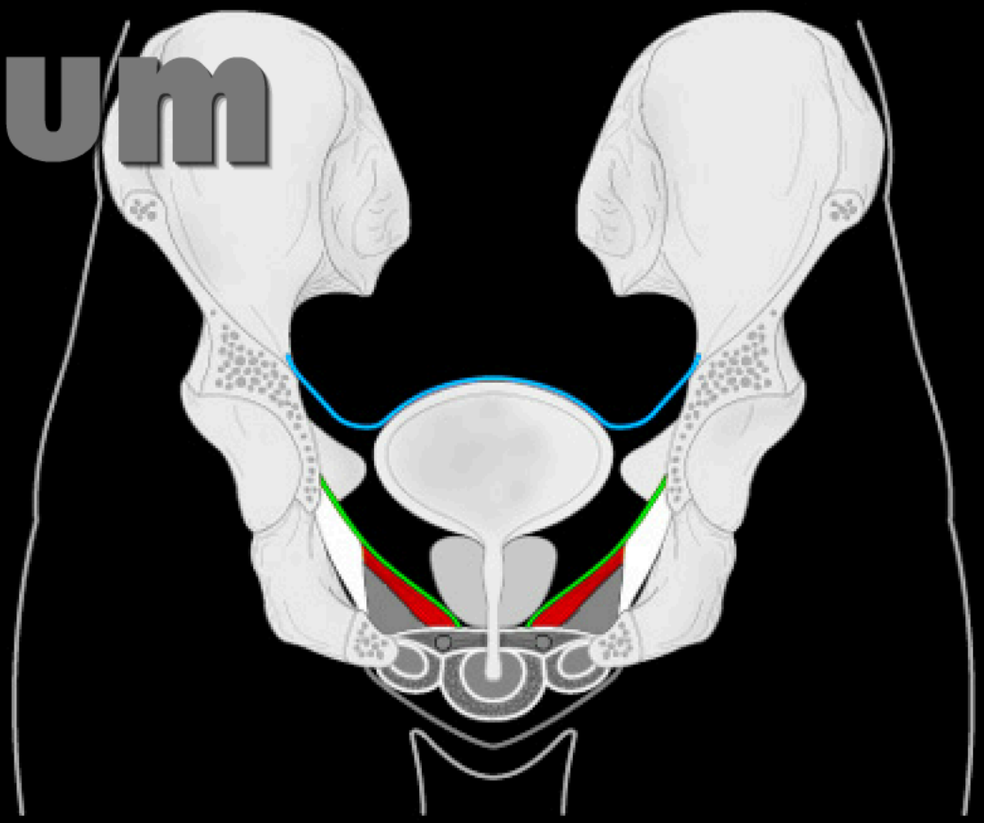

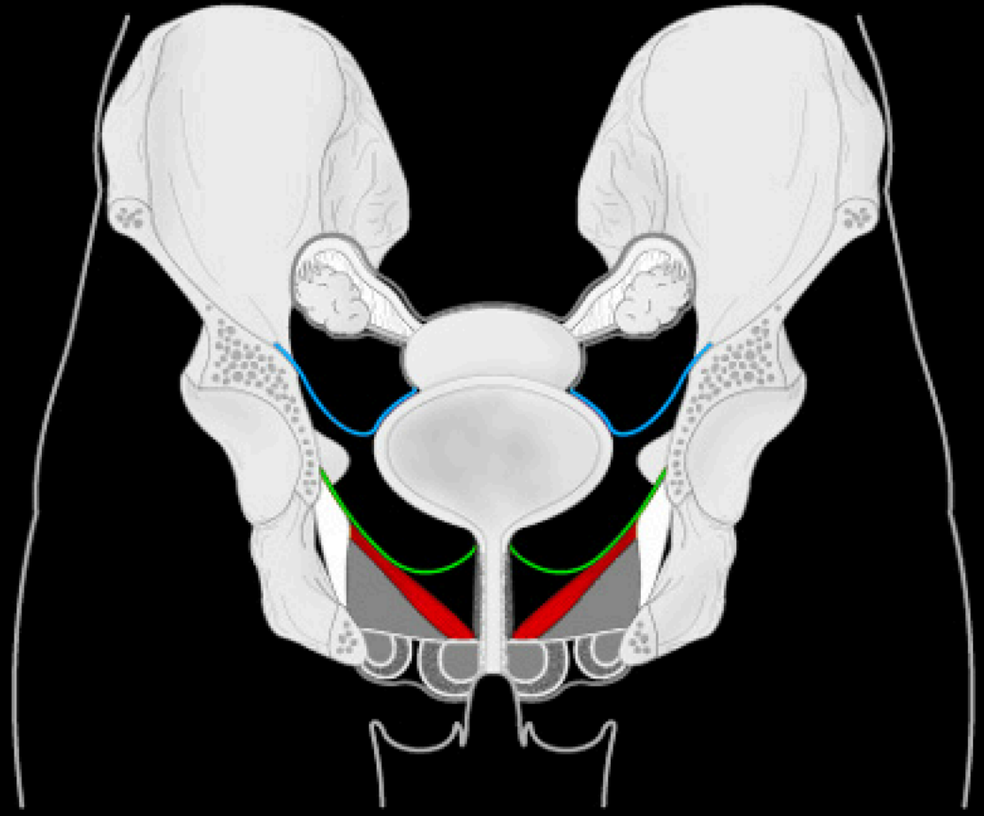

Contents

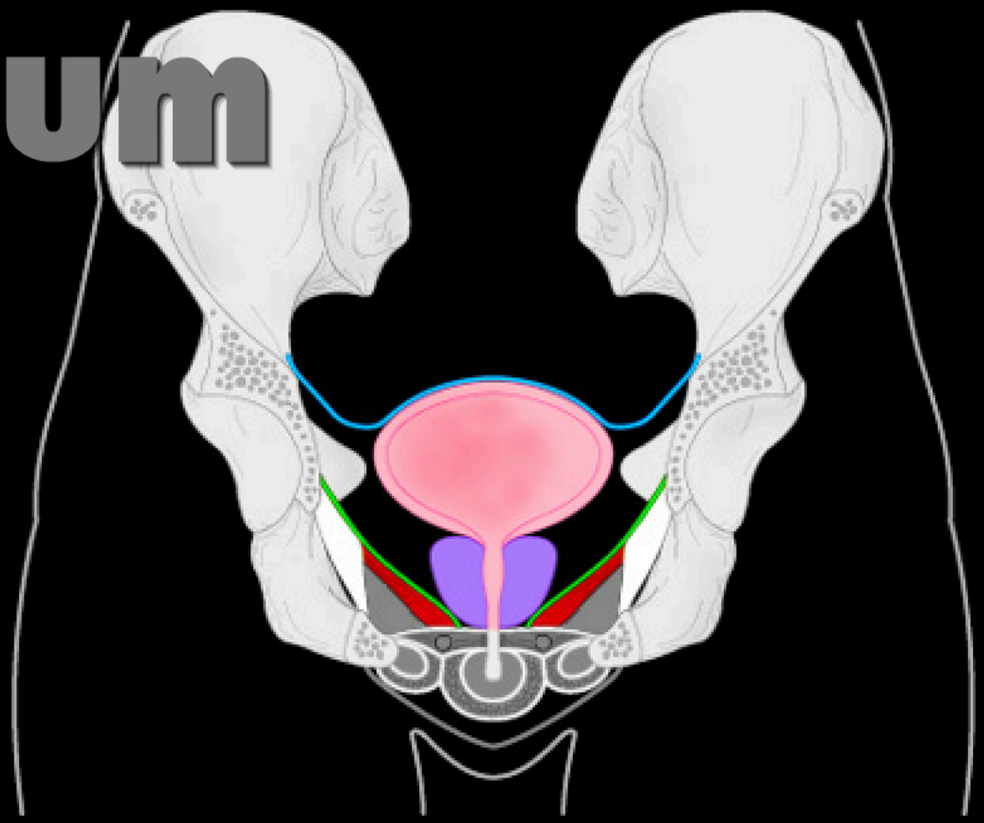

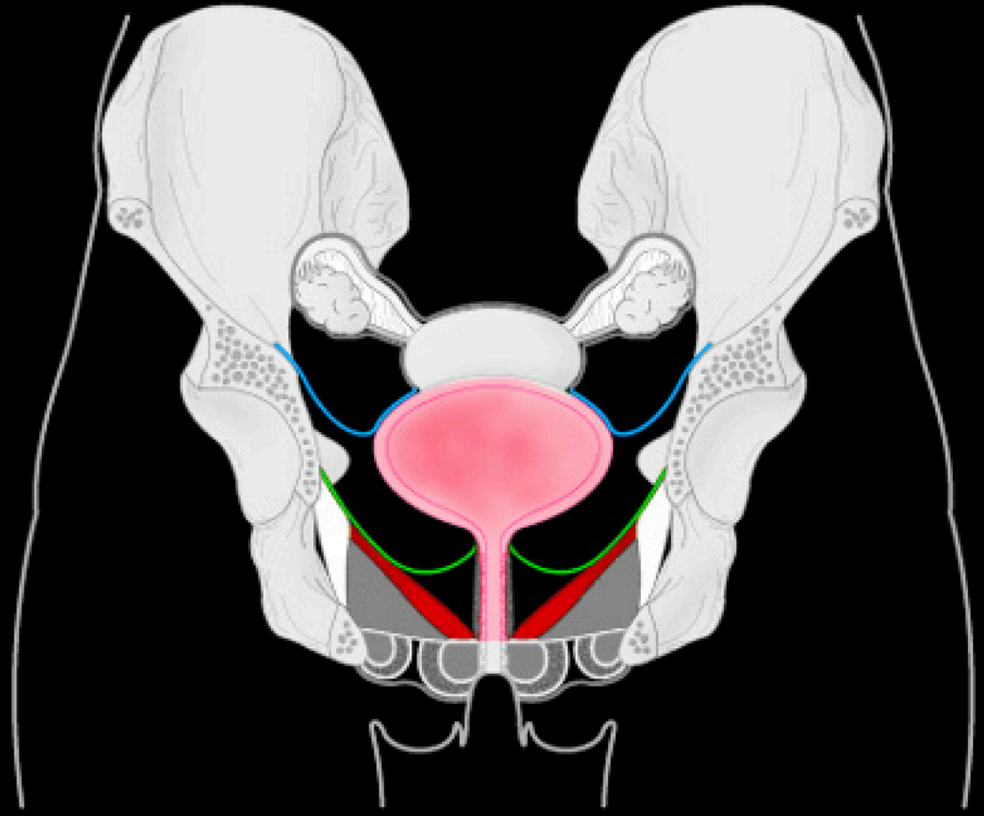

Pelvis/Perineum

Boundaries and Contents

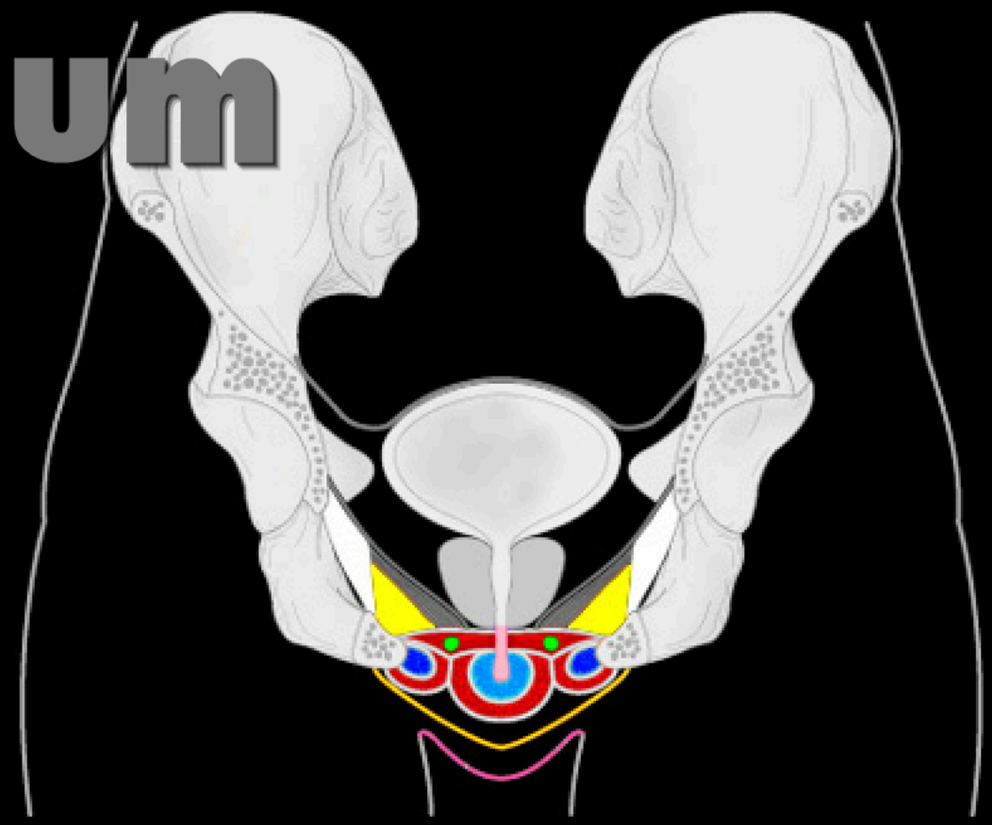

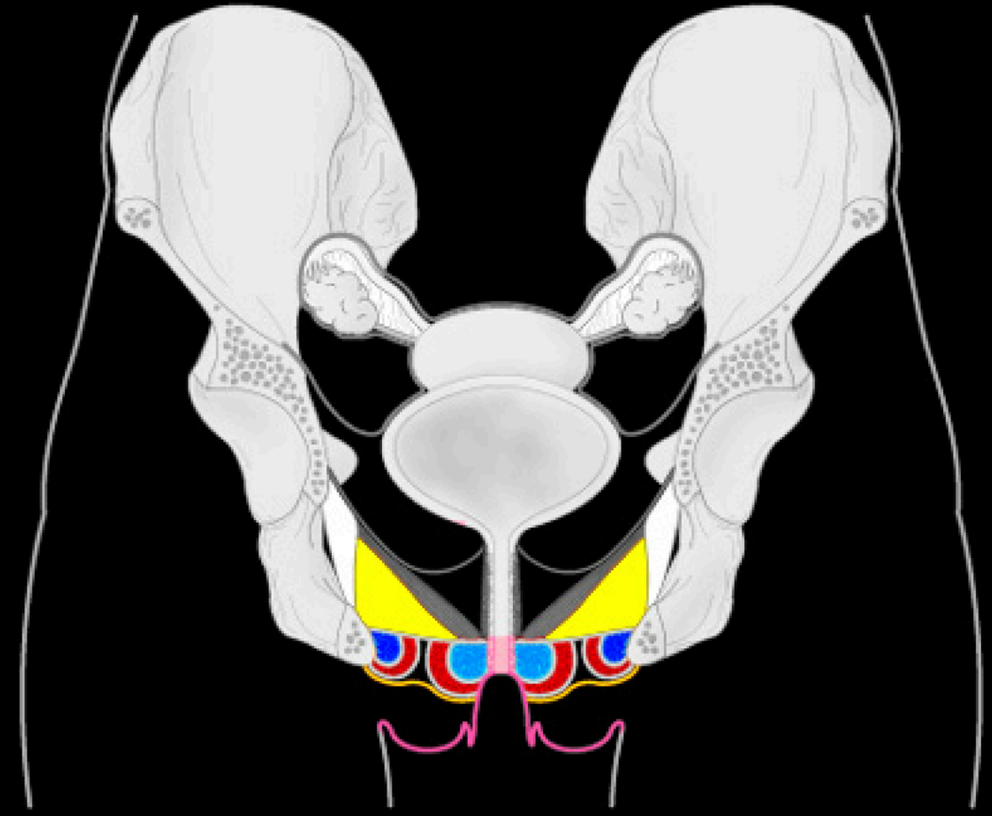

Regions of the Perineum

Ischioanal fossa

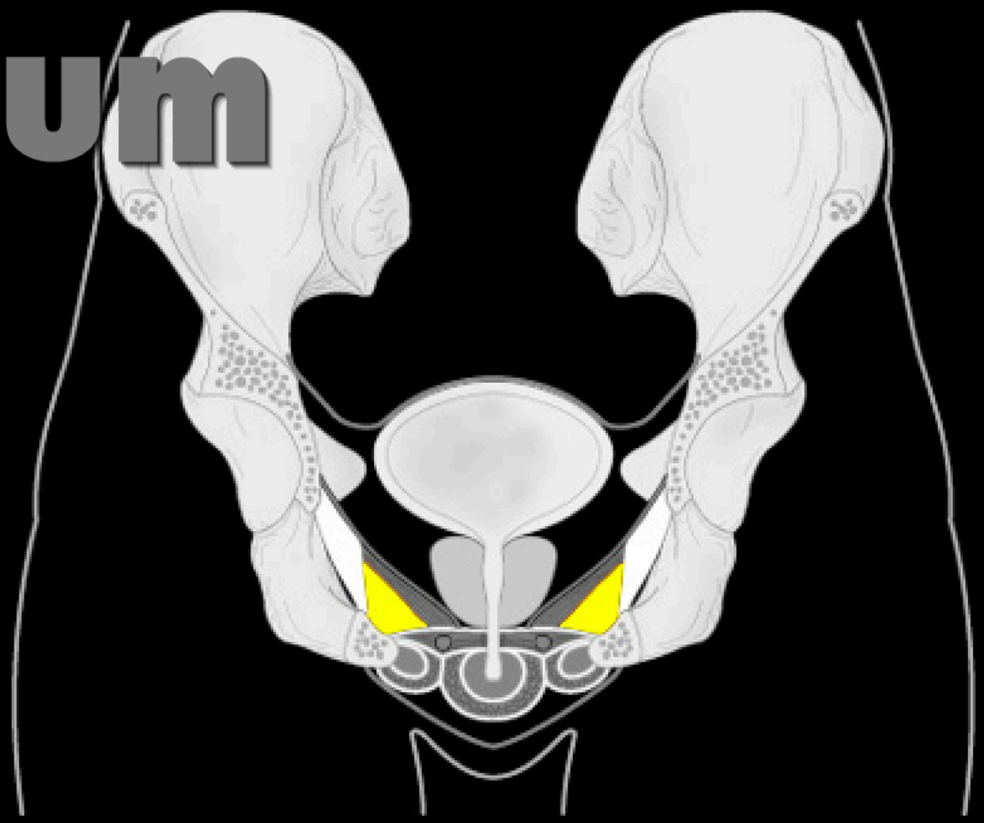

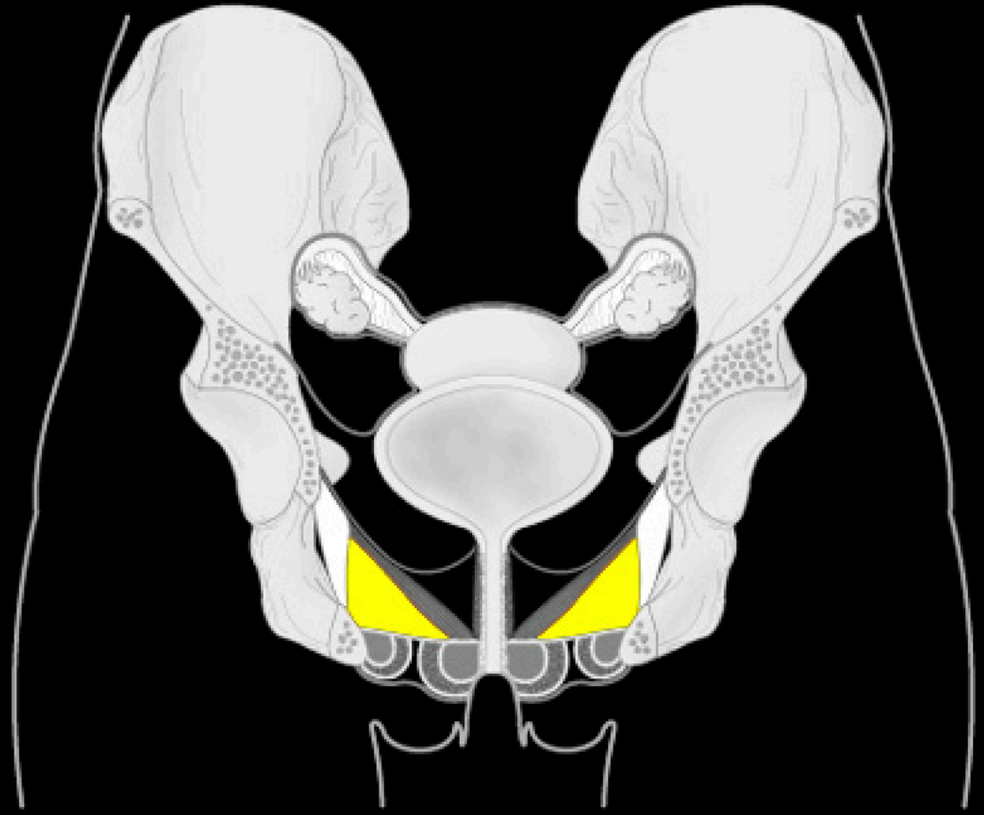

Regions of the Perineum

Deep perineal pouch

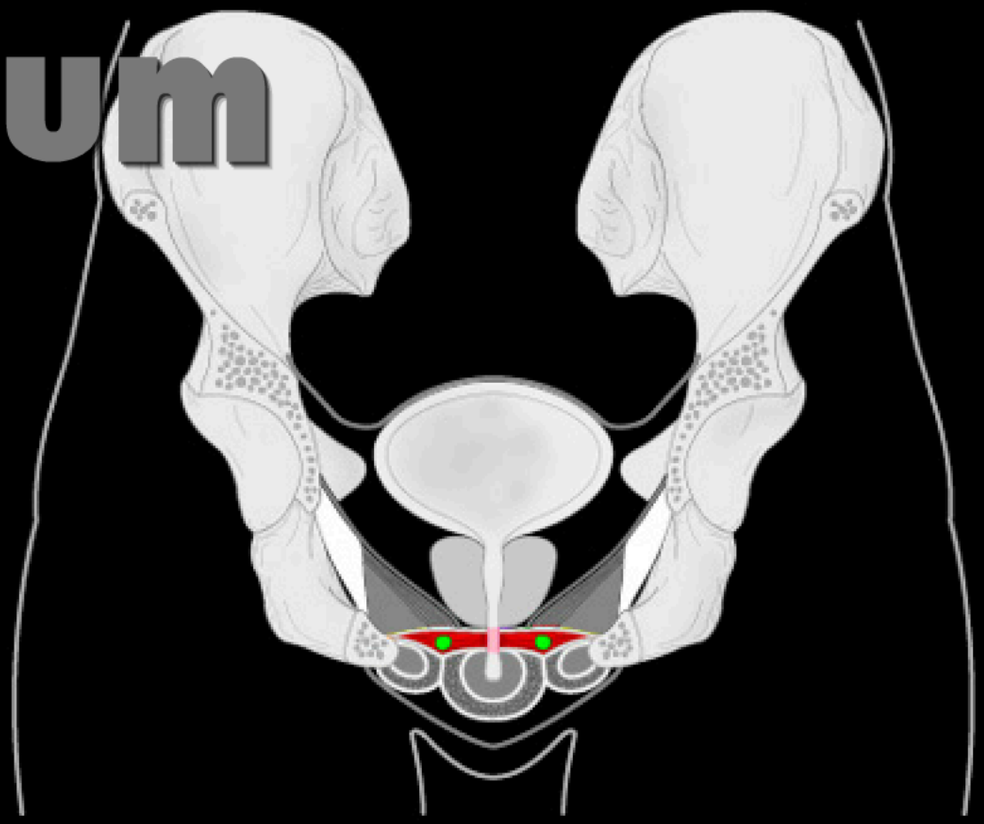

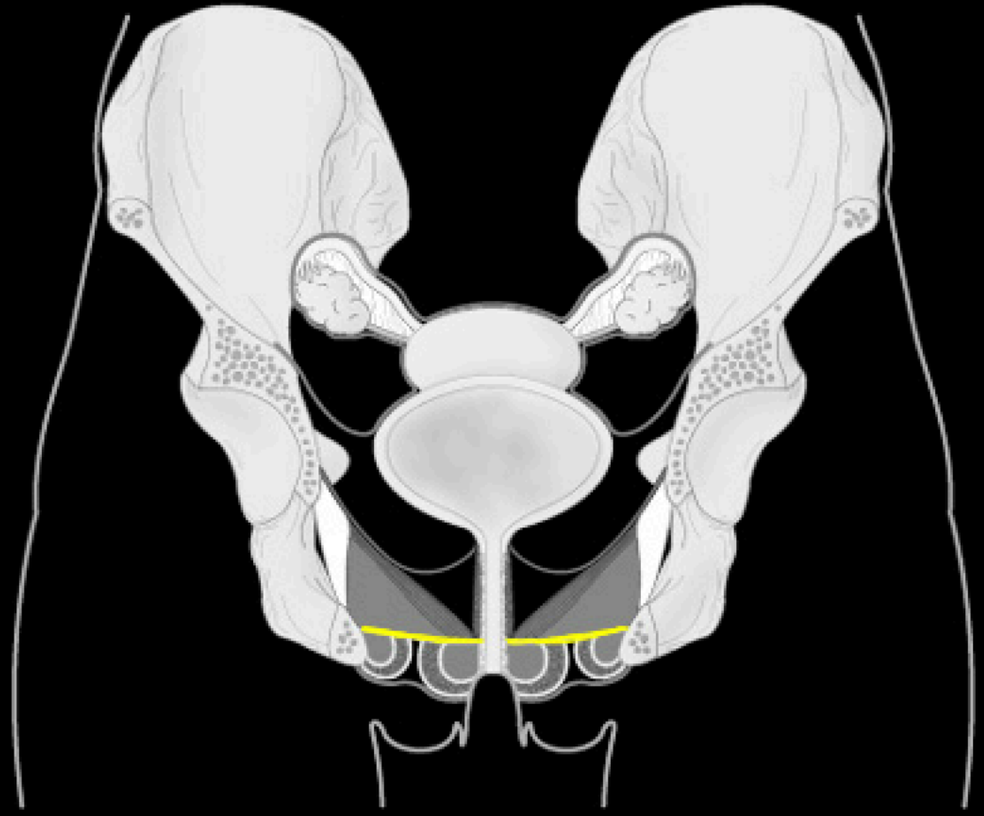

Regions of the Perineum

Deep perineal pouch

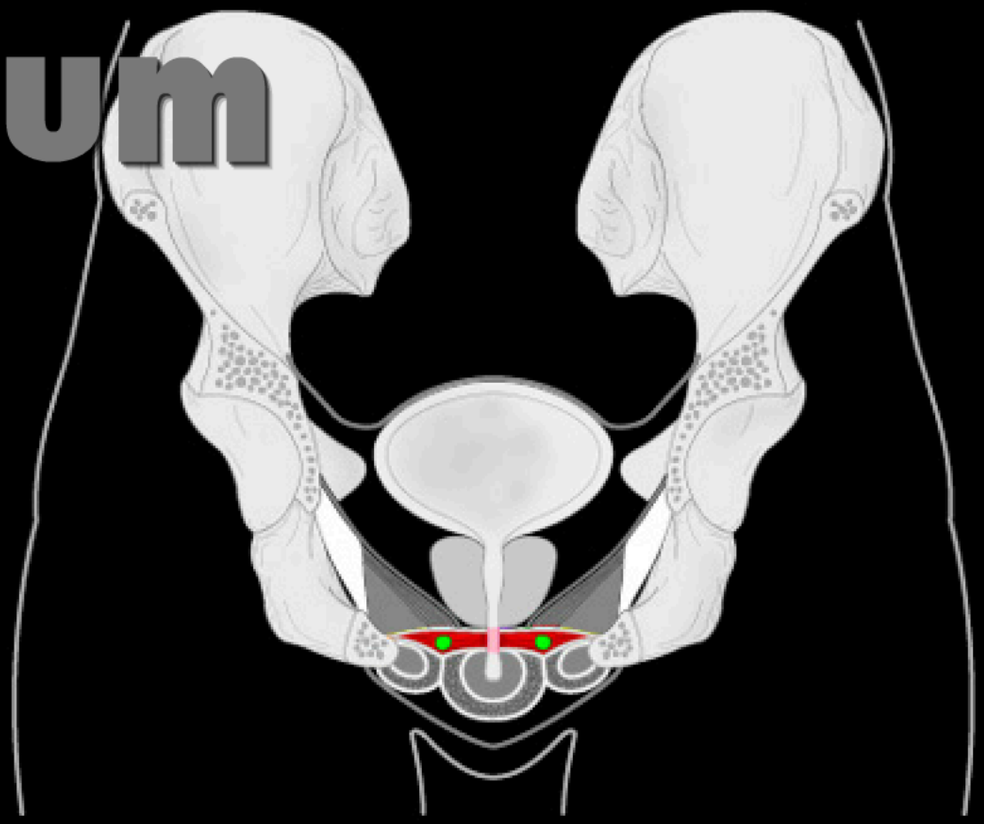

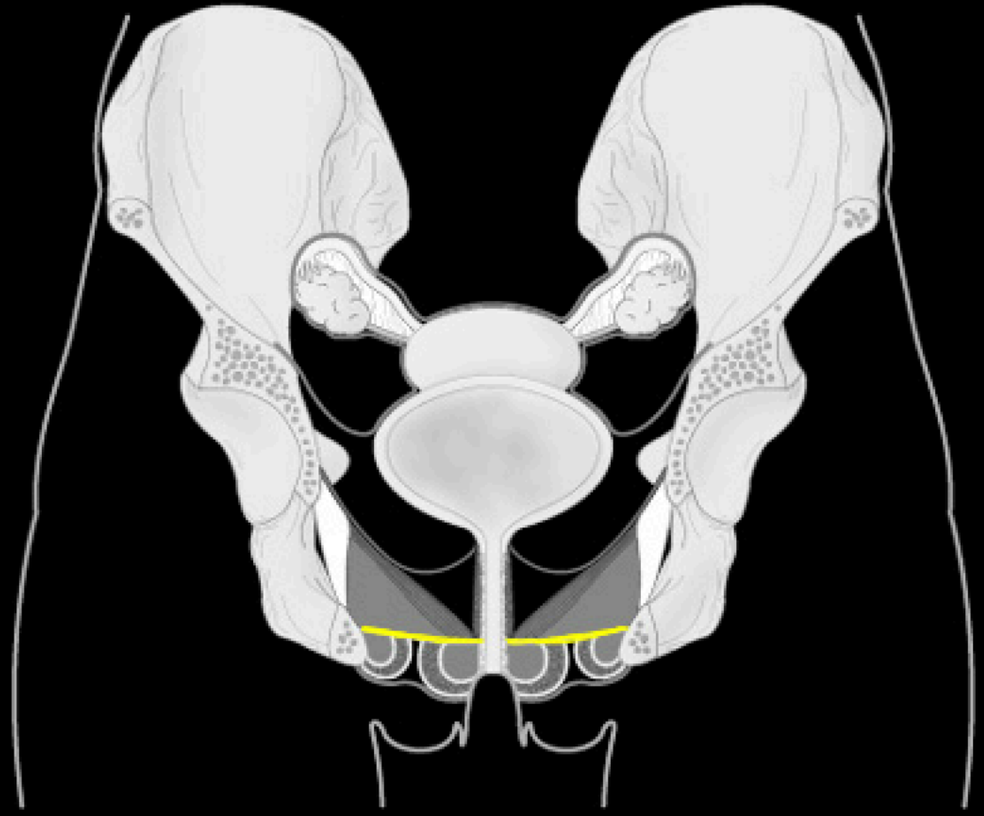

Regions of the Perineum

Superficial perineal pouch

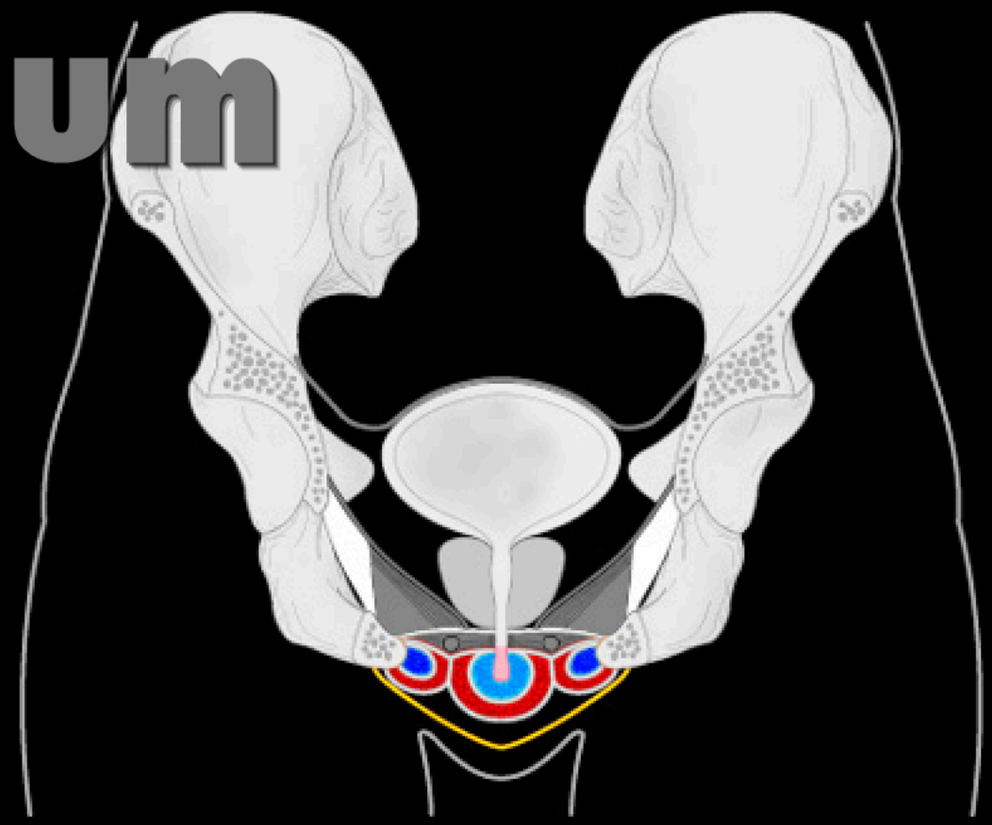

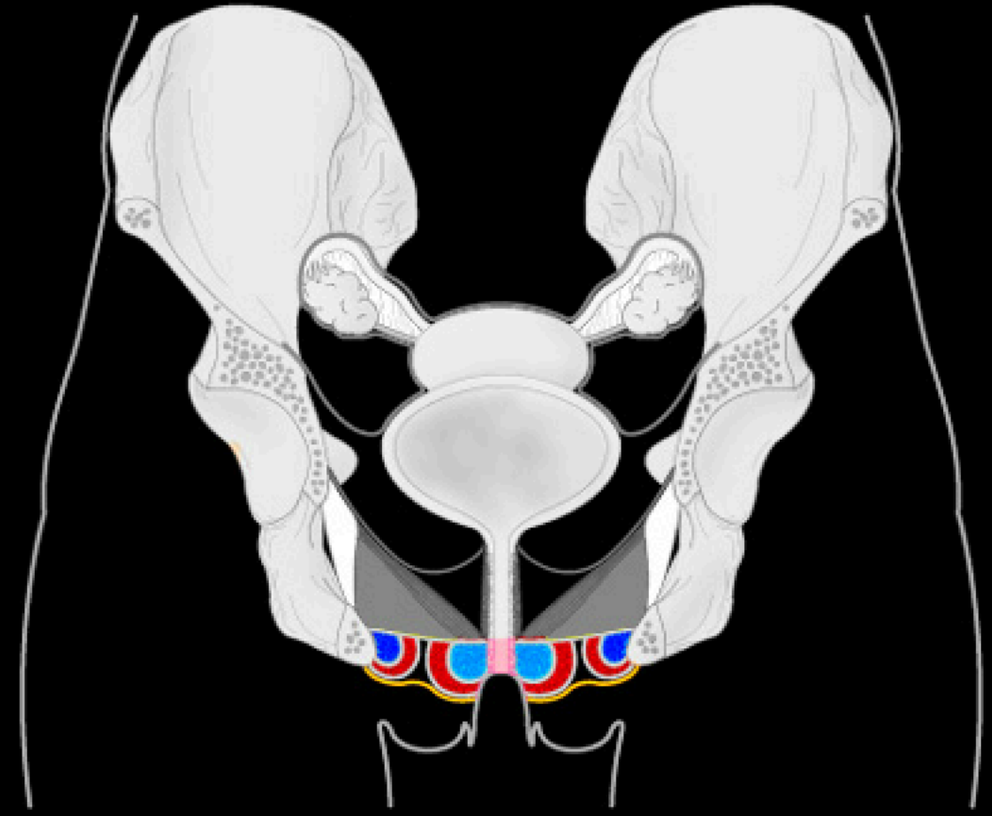

Pelvis/Perineum

Pelvis and Perineum

Reviewing the Anatomy

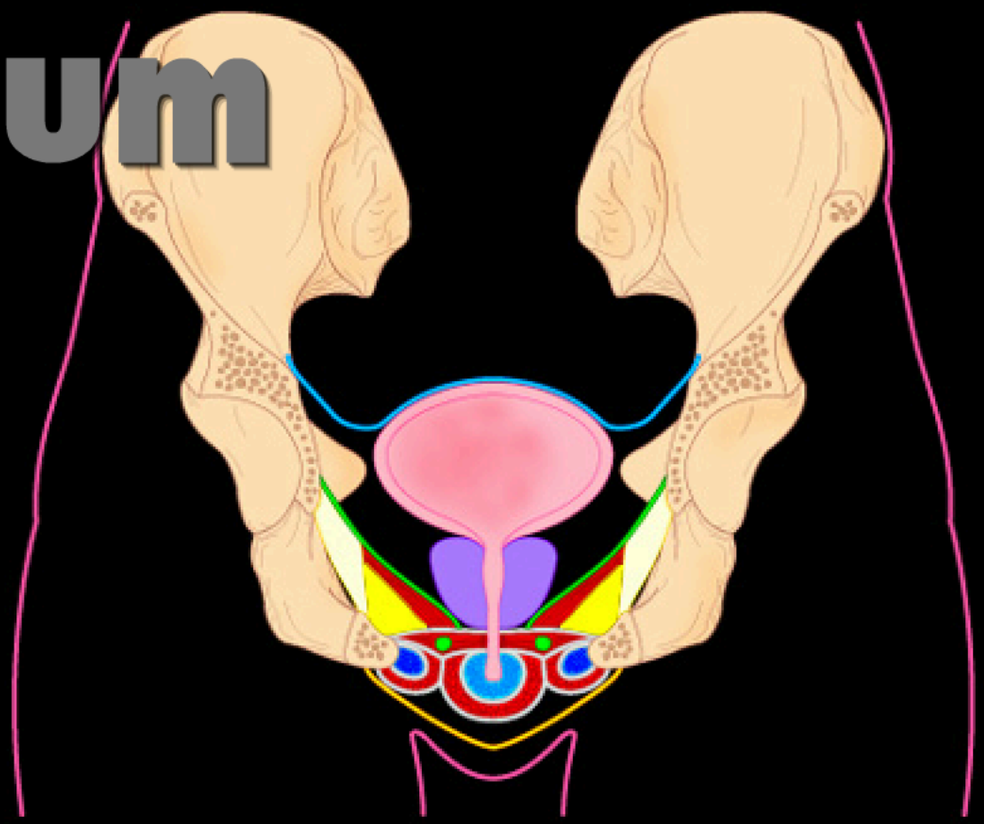

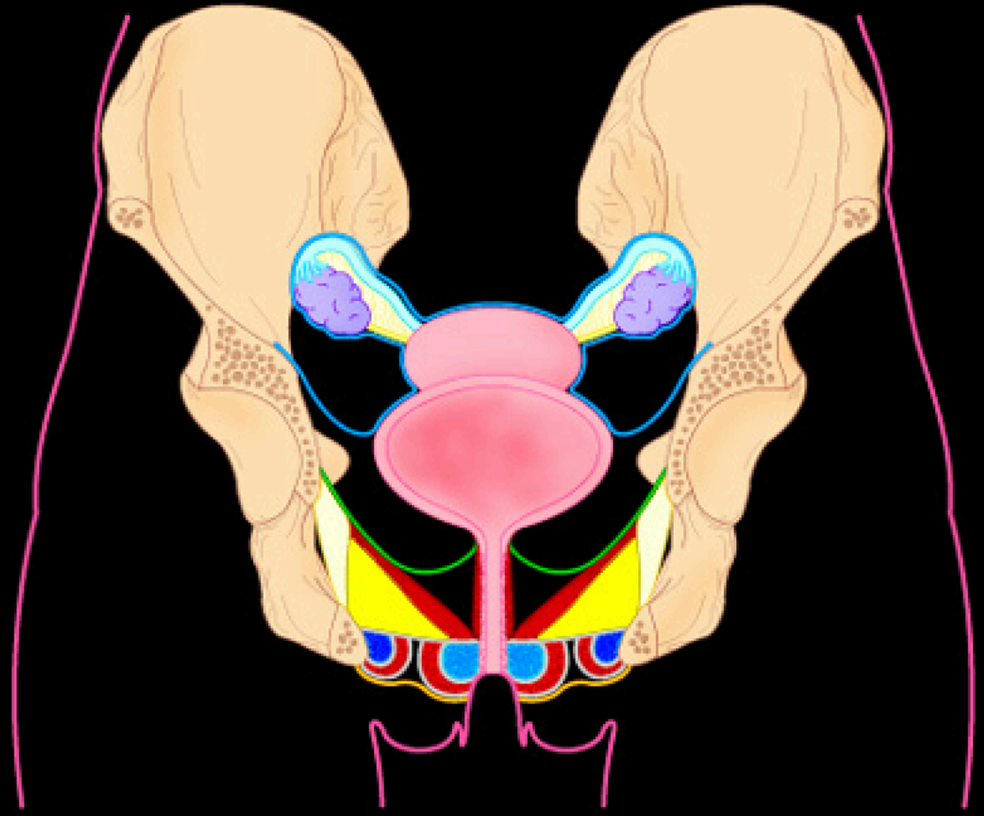

Internal Iliac Somatic Arteries

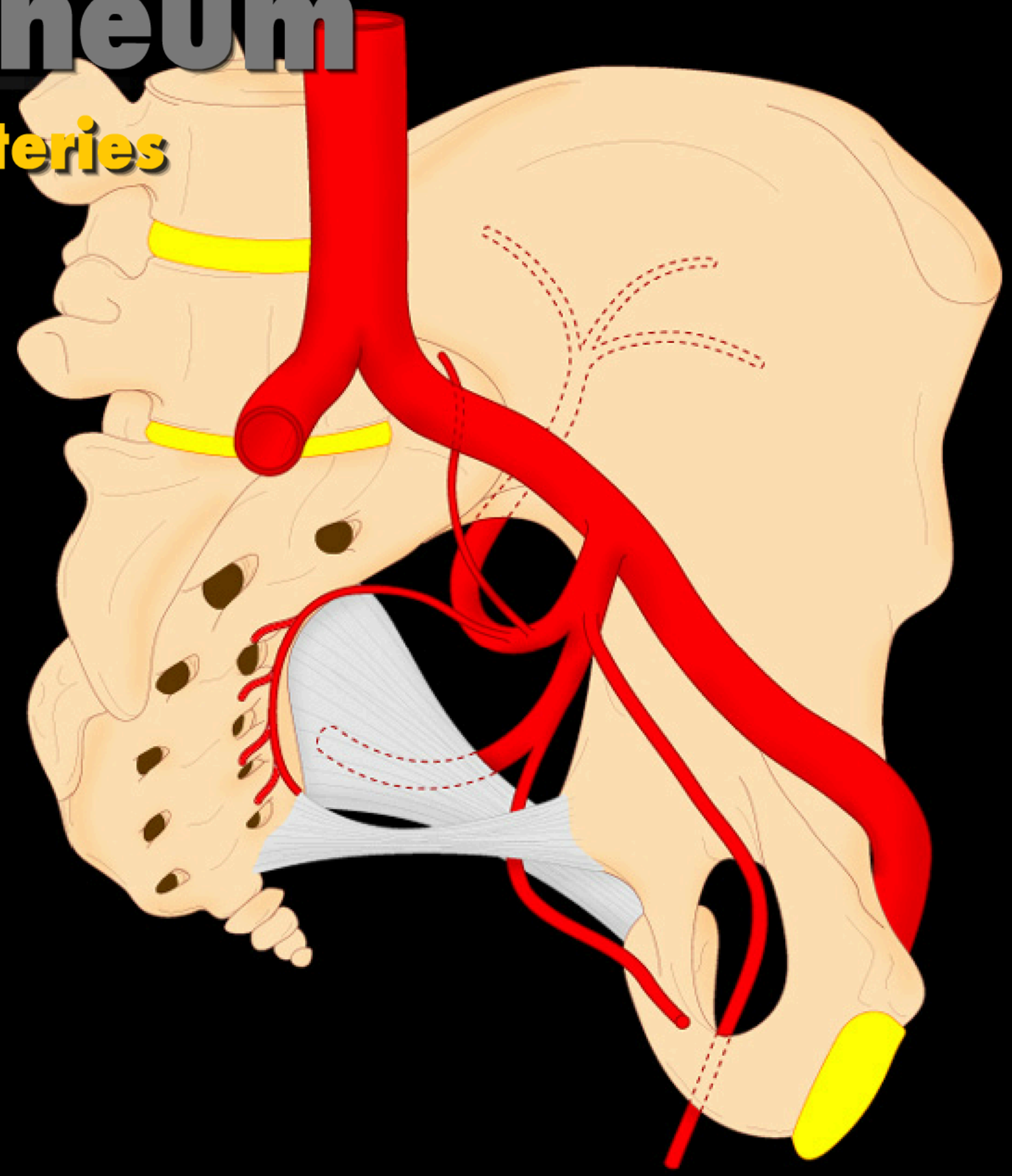

Pelvis/Perineal Blood Vessels

Review of Major Pathways

- Aorta
- Common iliac artery

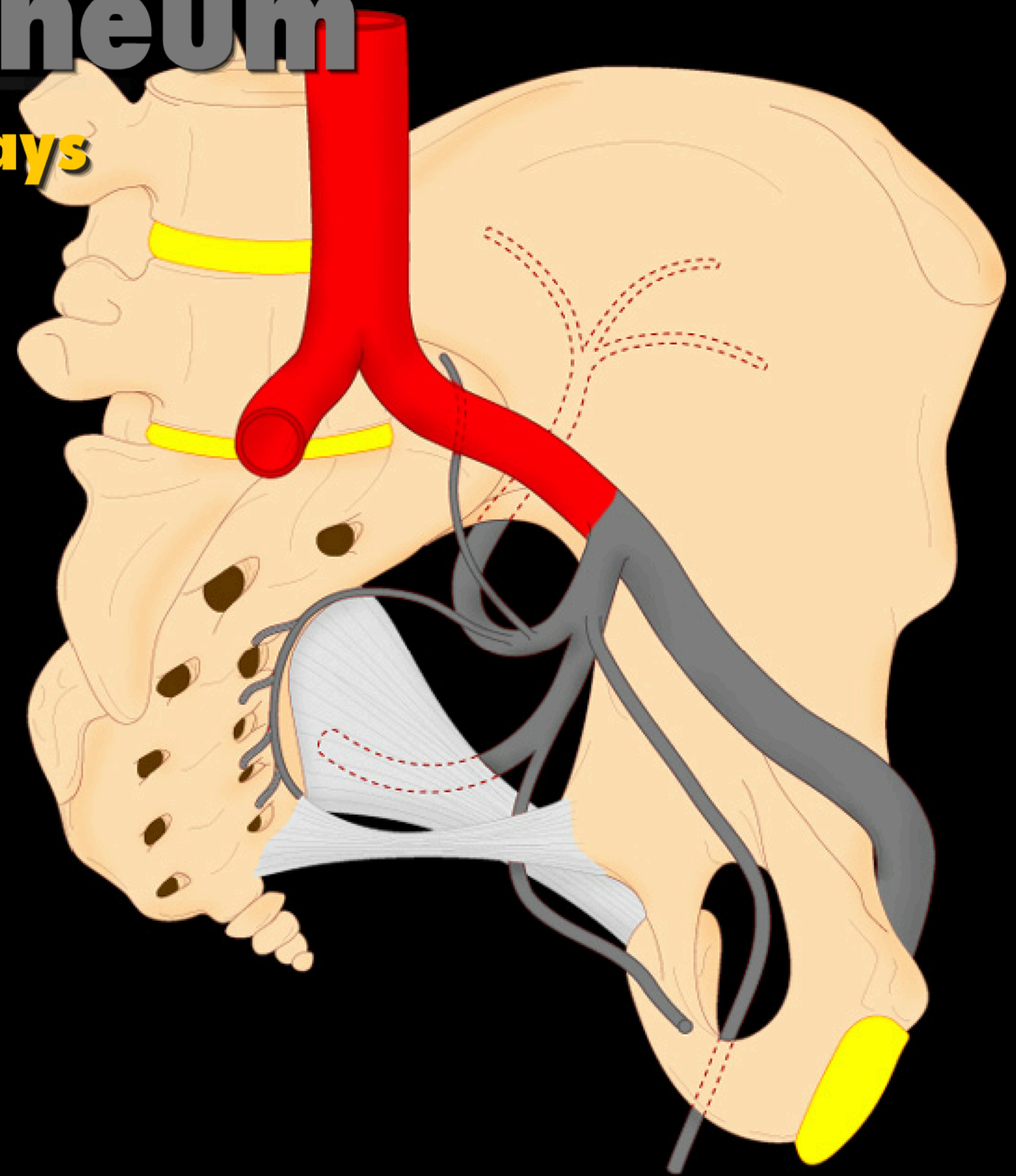

Pelvis/Perineal Blood Vessels

Internal Iliac Somatic Arteries

Internal iliac artery

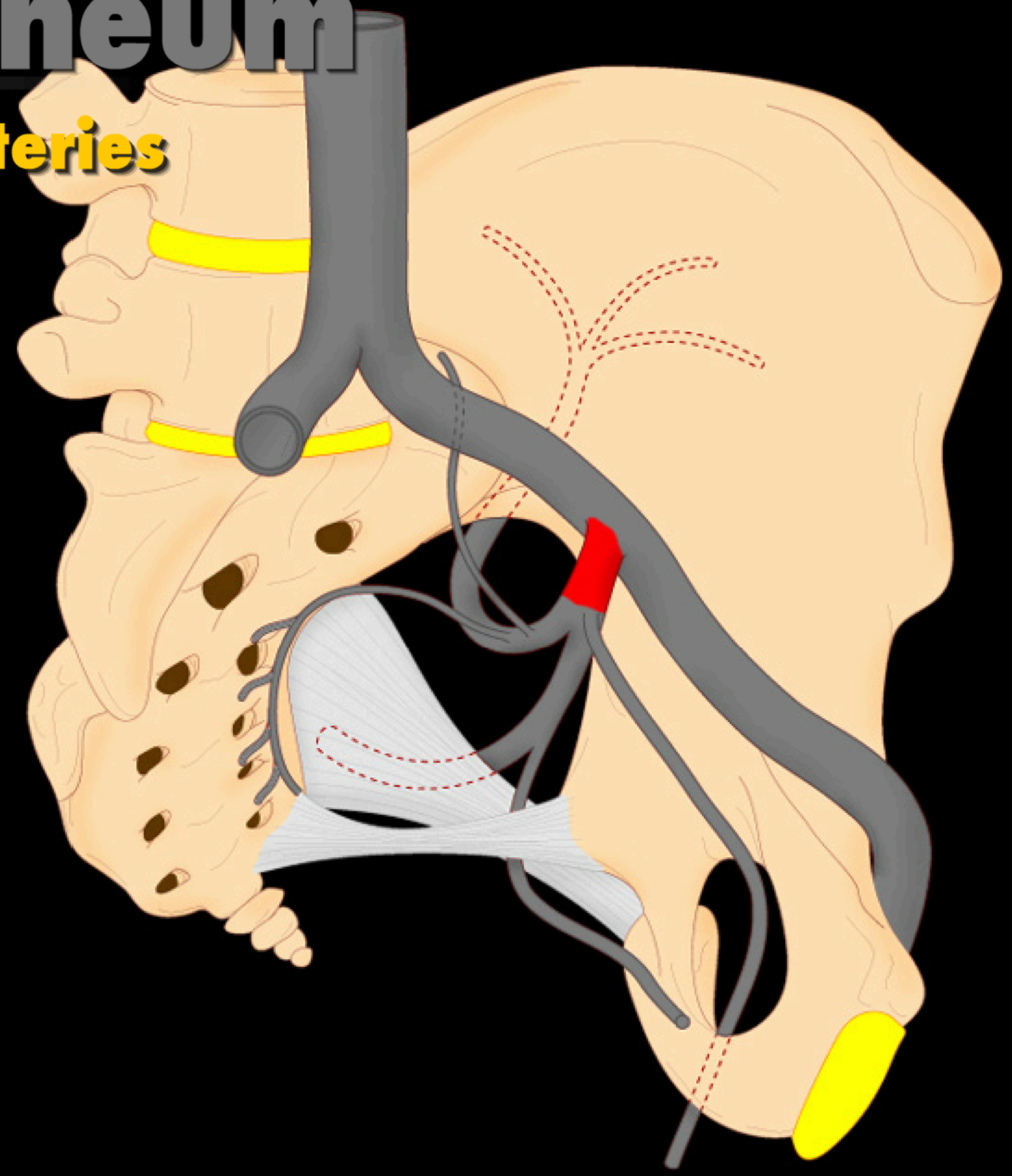

Pelvis/Perineal Blood Vessels

Internal Iliac Somatic Arteries

Iliolumbar artery

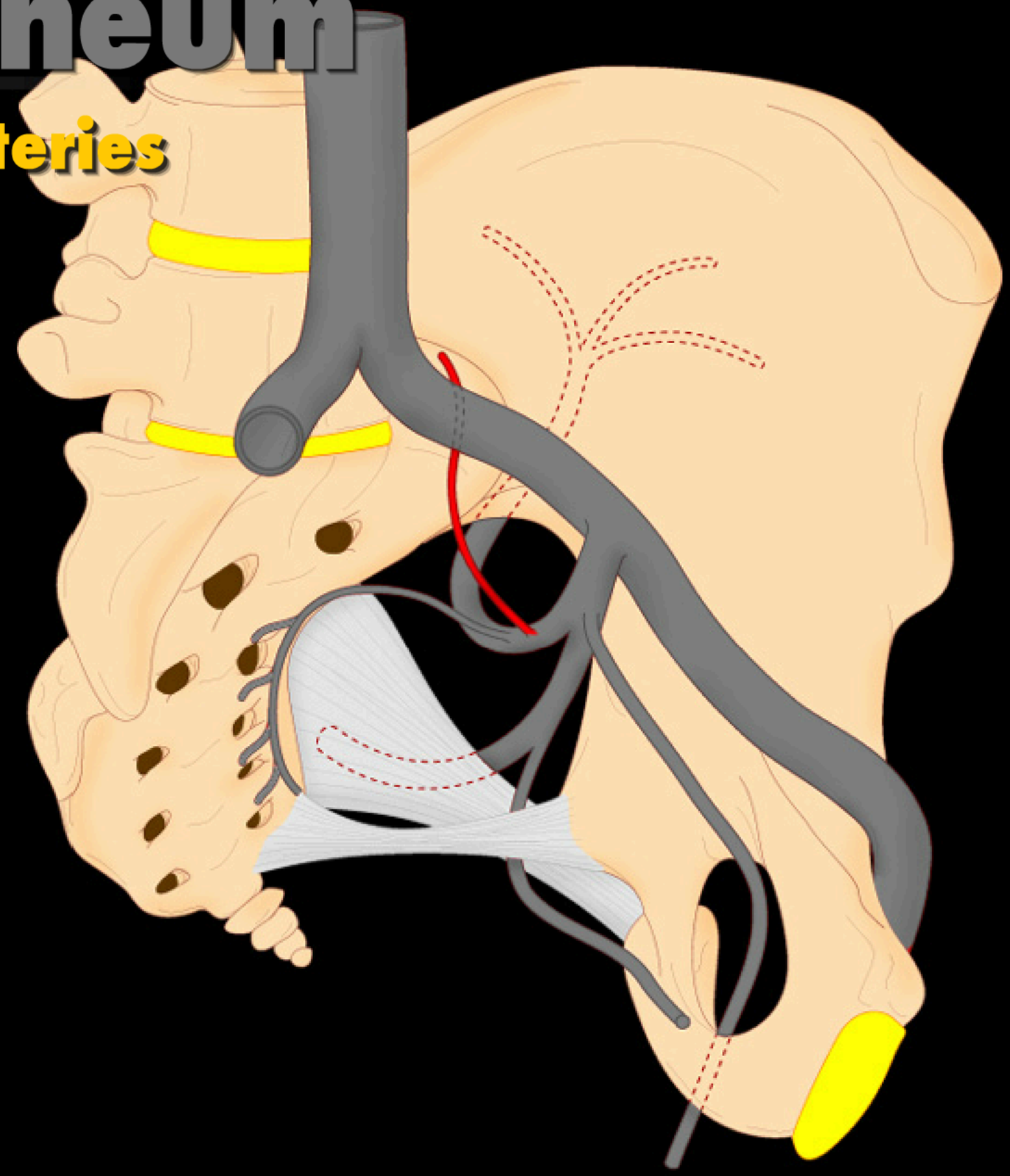

Pelvis/Perineal Blood Vessels

Internal Iliac Somatic Arteries

Lateral sacral artery

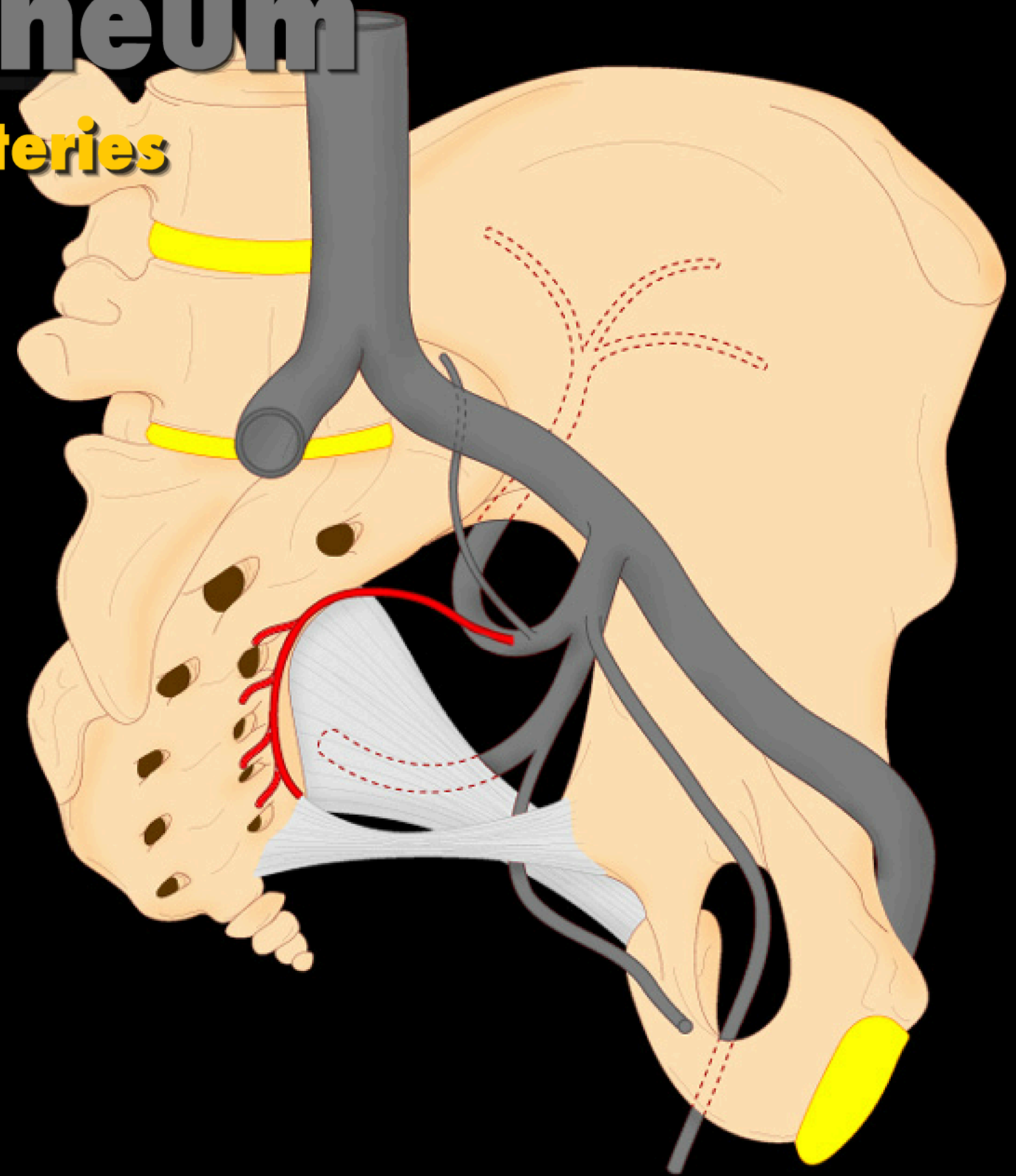

Pelvis/Perineal Blood Vessels

Internal Iliac Somatic Arteries

Superior gluteal artery

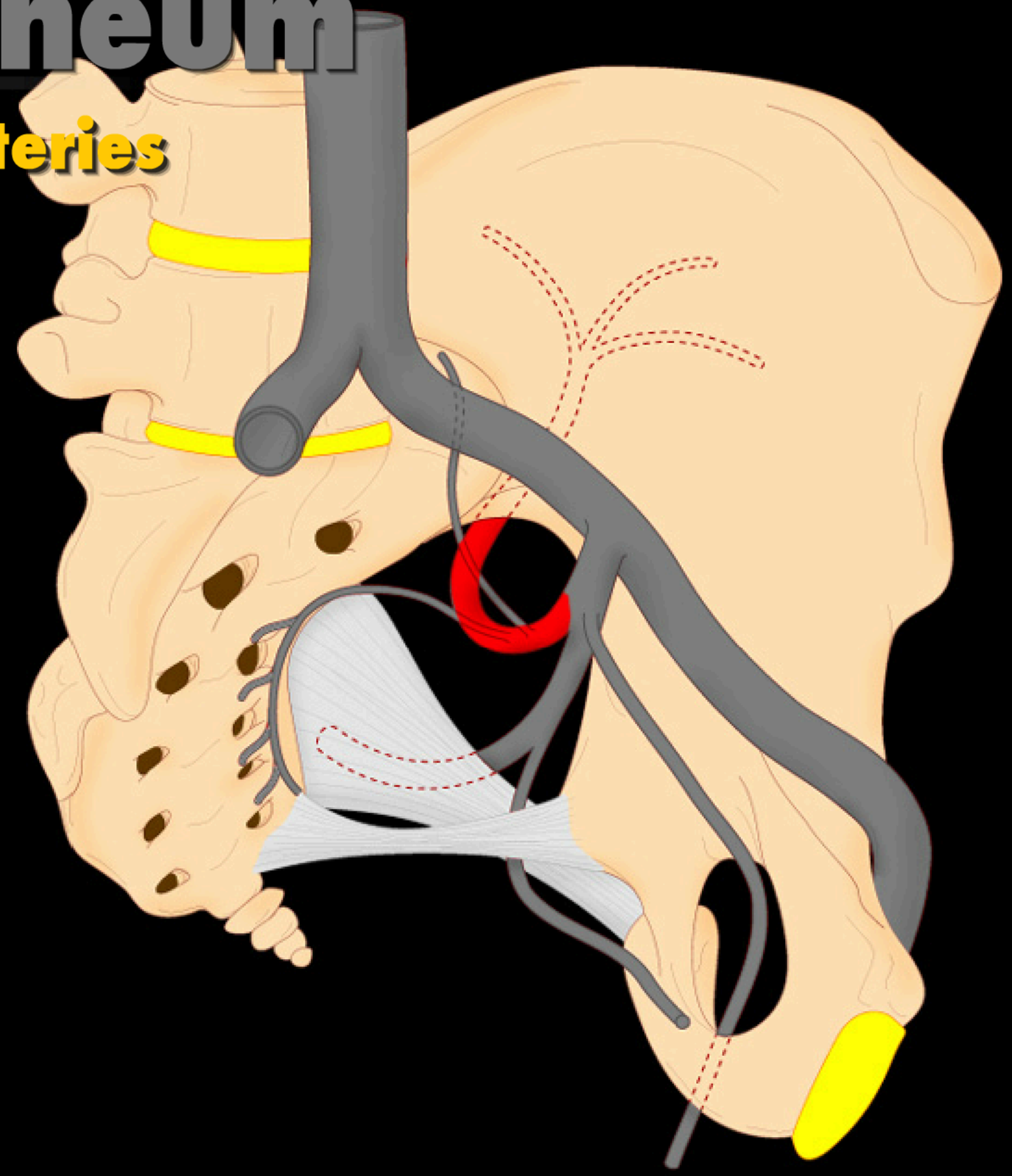

Pelvis/Perineal Blood Vessels

Internal Iliac Somatic Arteries

Inferior gluteal artery

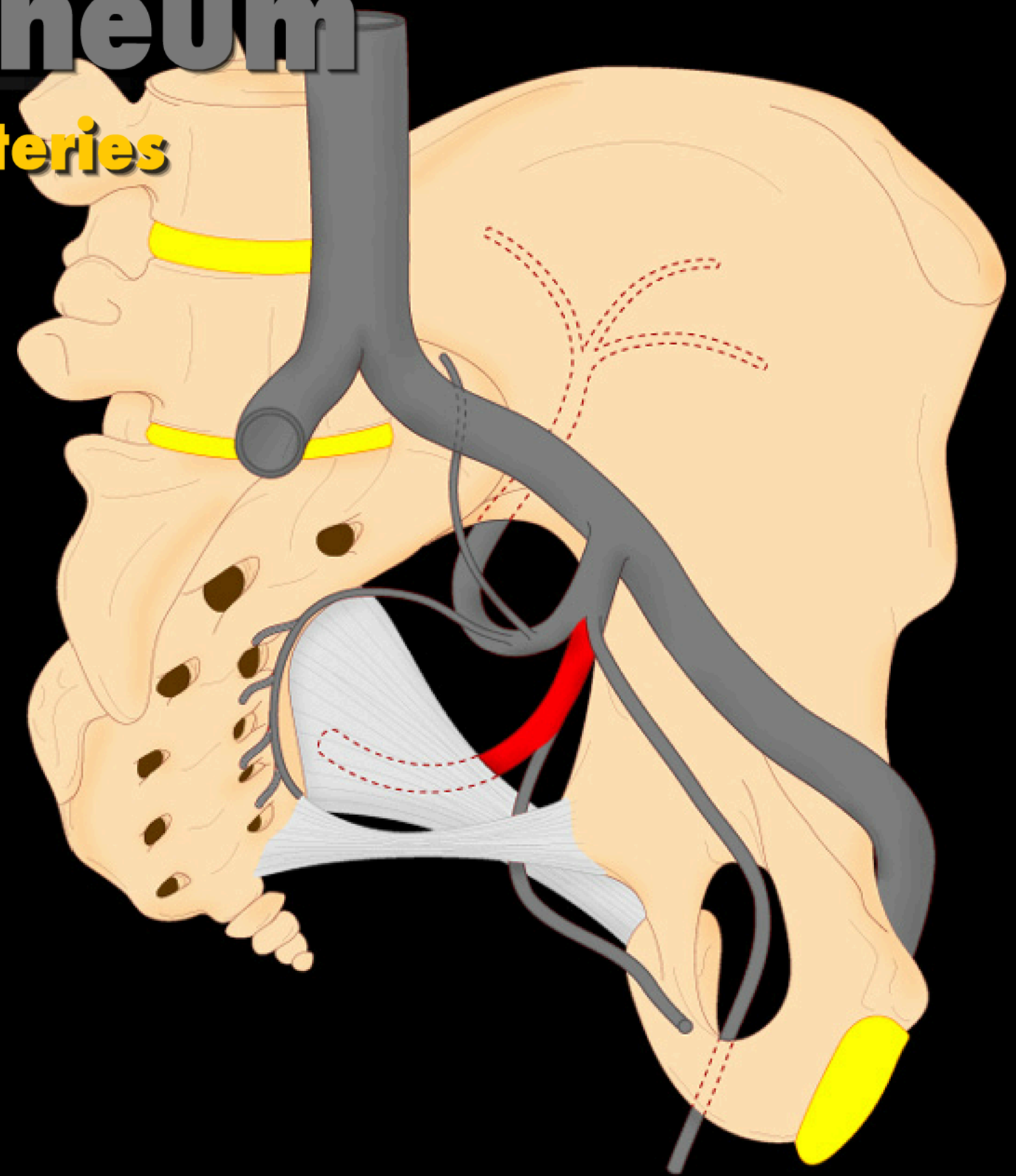

Pelvis/Perineal Blood Vessels

Internal Iliac Somatic Arteries

Obturator artery

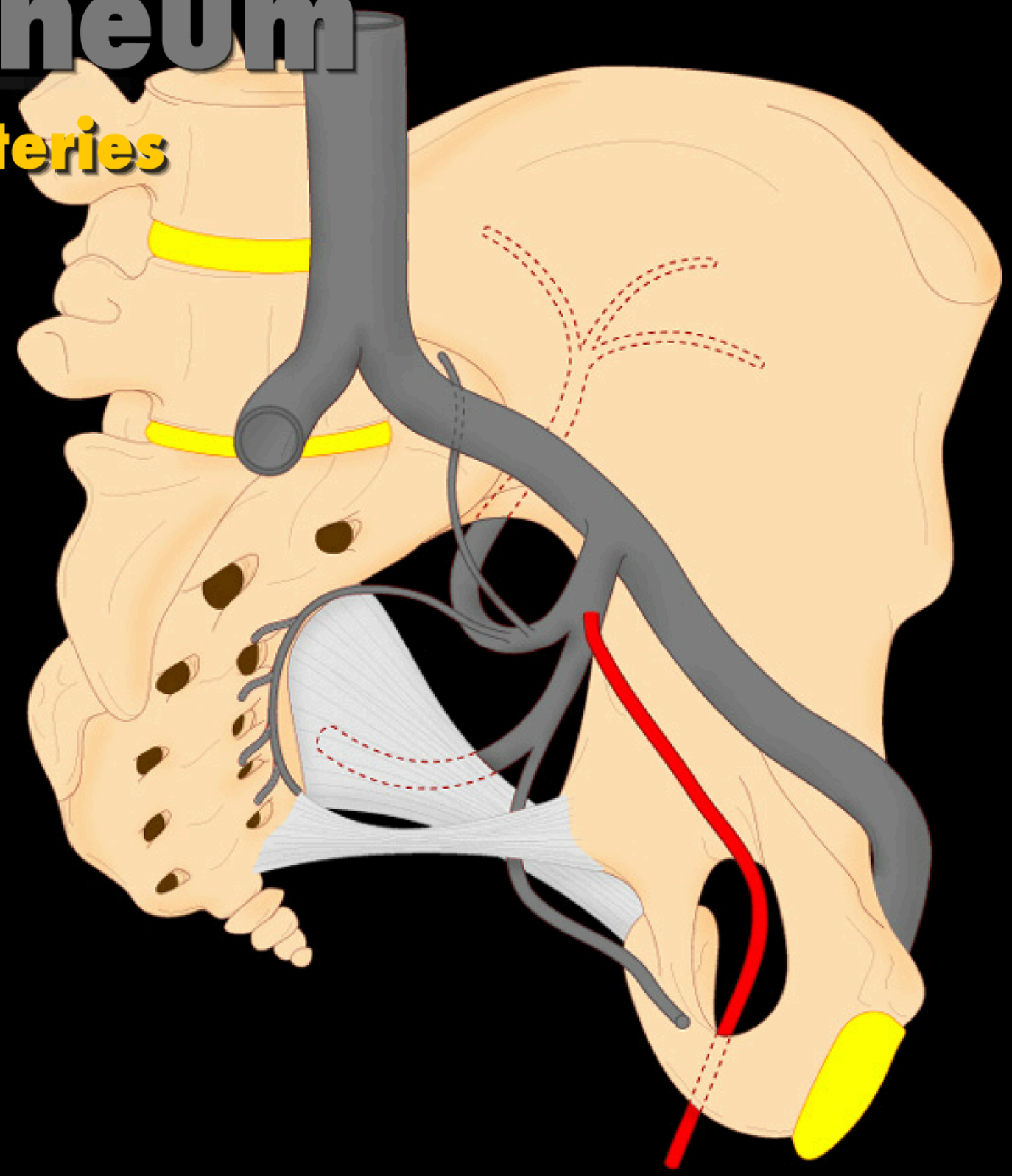

Pelvis/Perineal Blood Vessels

Internal Iliac Somatic Arteries

Internal pudendal artery

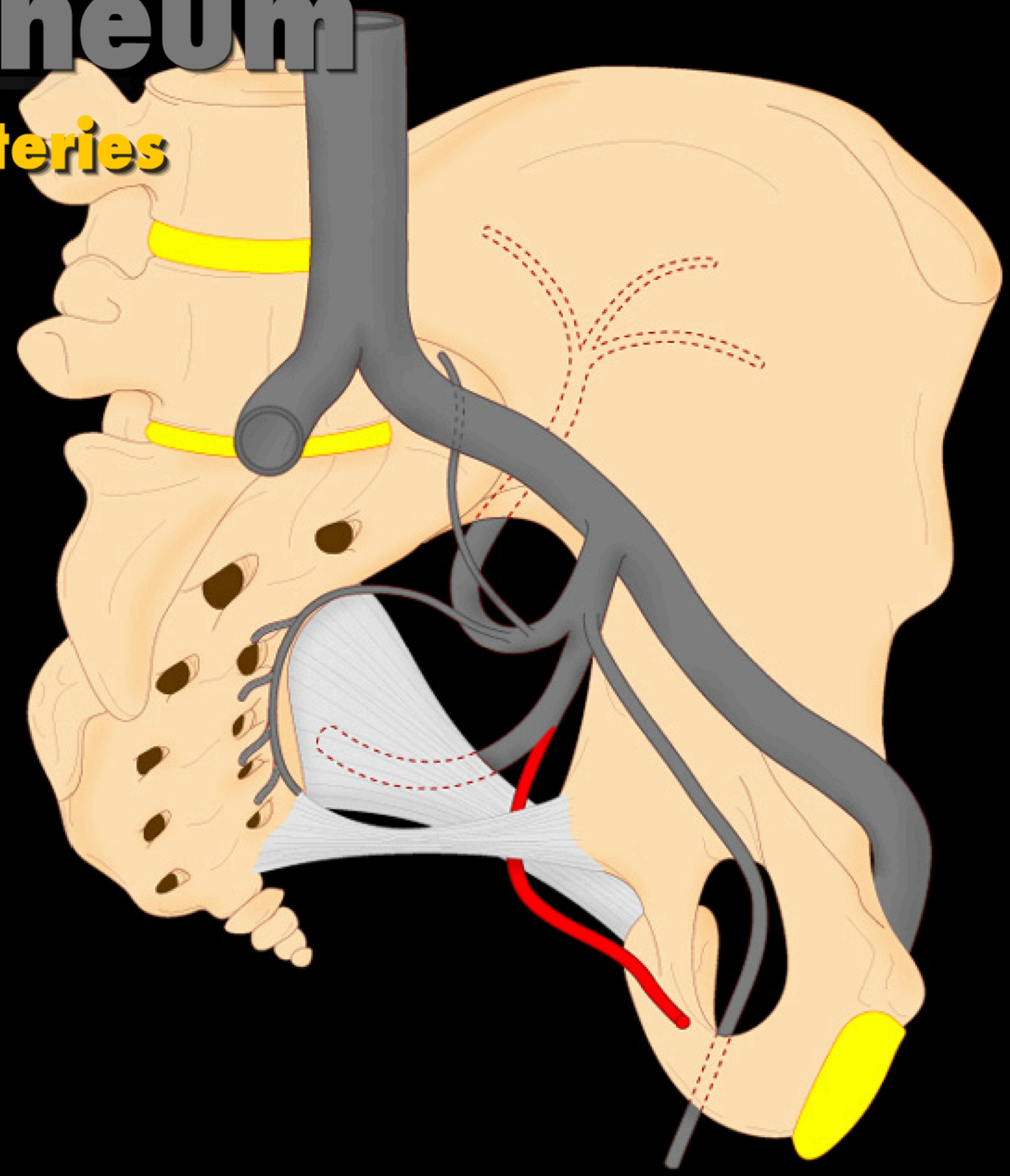

Pelvis/Perineal Blood Vessels

Internal Iliac Visceral Arteries

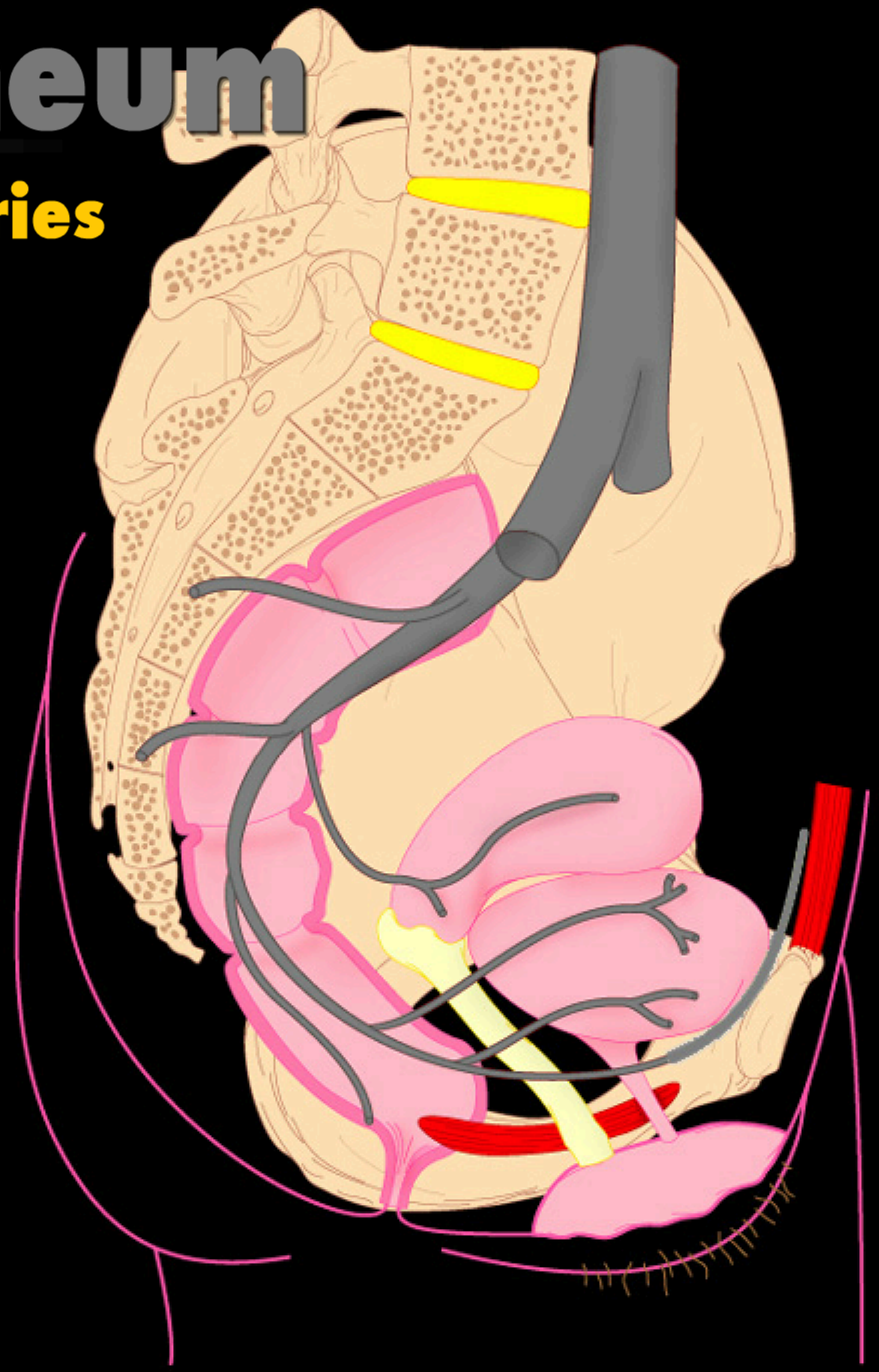

Pelvis/Perineal Blood Vessels

Internal Iliac Visceral Arteries

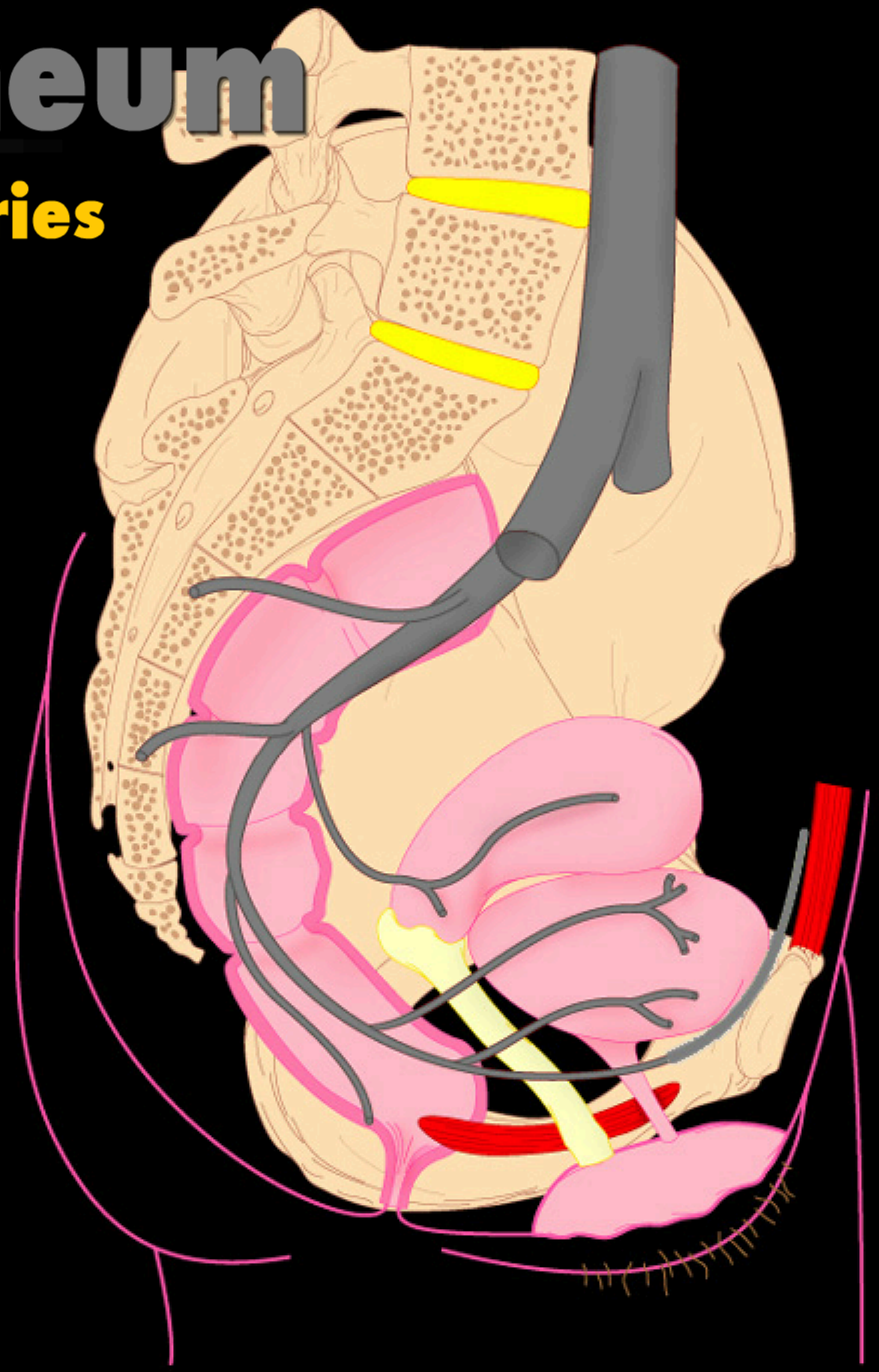

Pelvis/Perineal Blood Vessels

Internal Iliac Visceral Arteries

Middle rectal artery

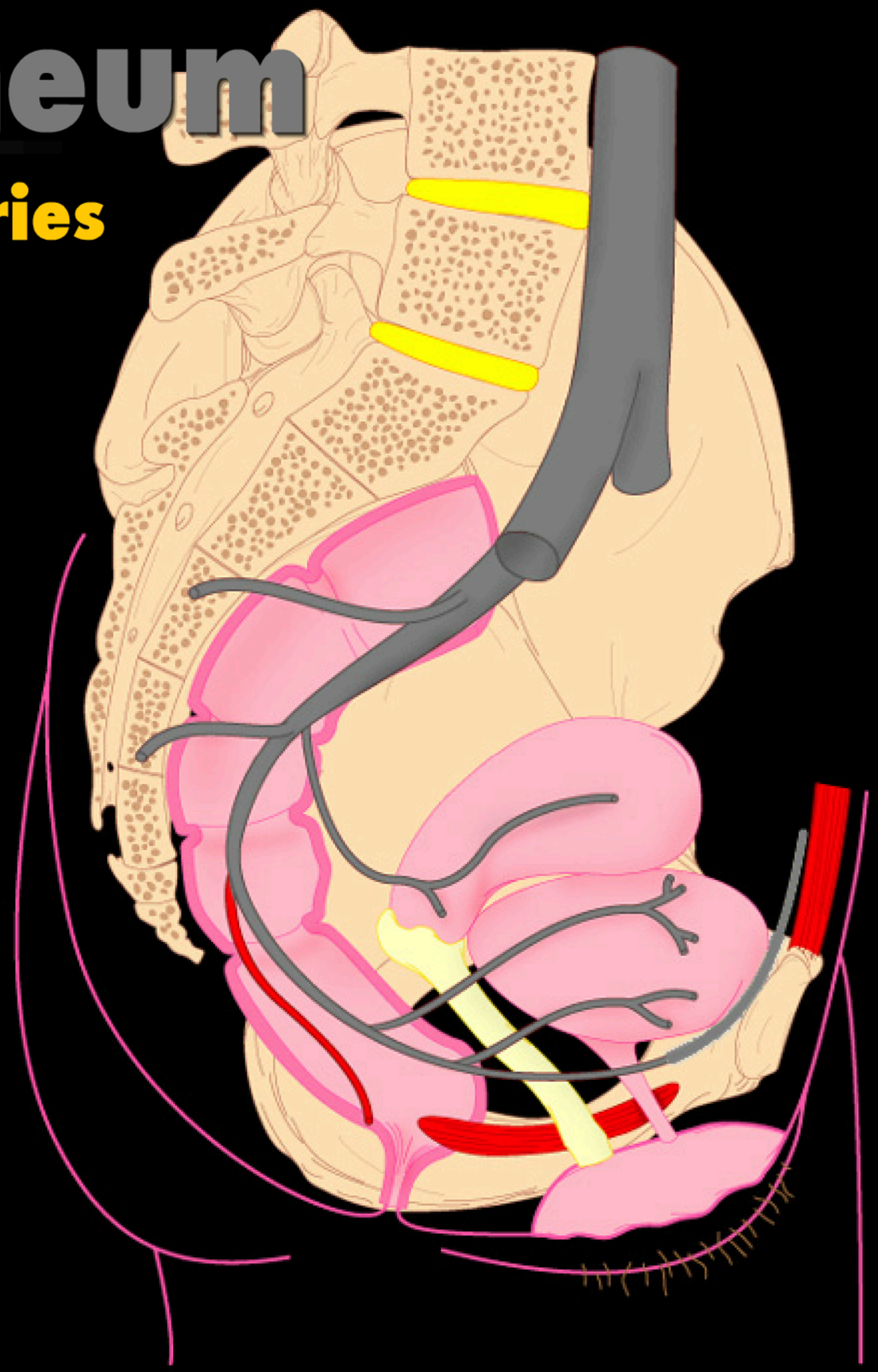

Pelvis/Perineal Blood Vessels

Internal Iliac Visceral Arteries

Superior vesical artery

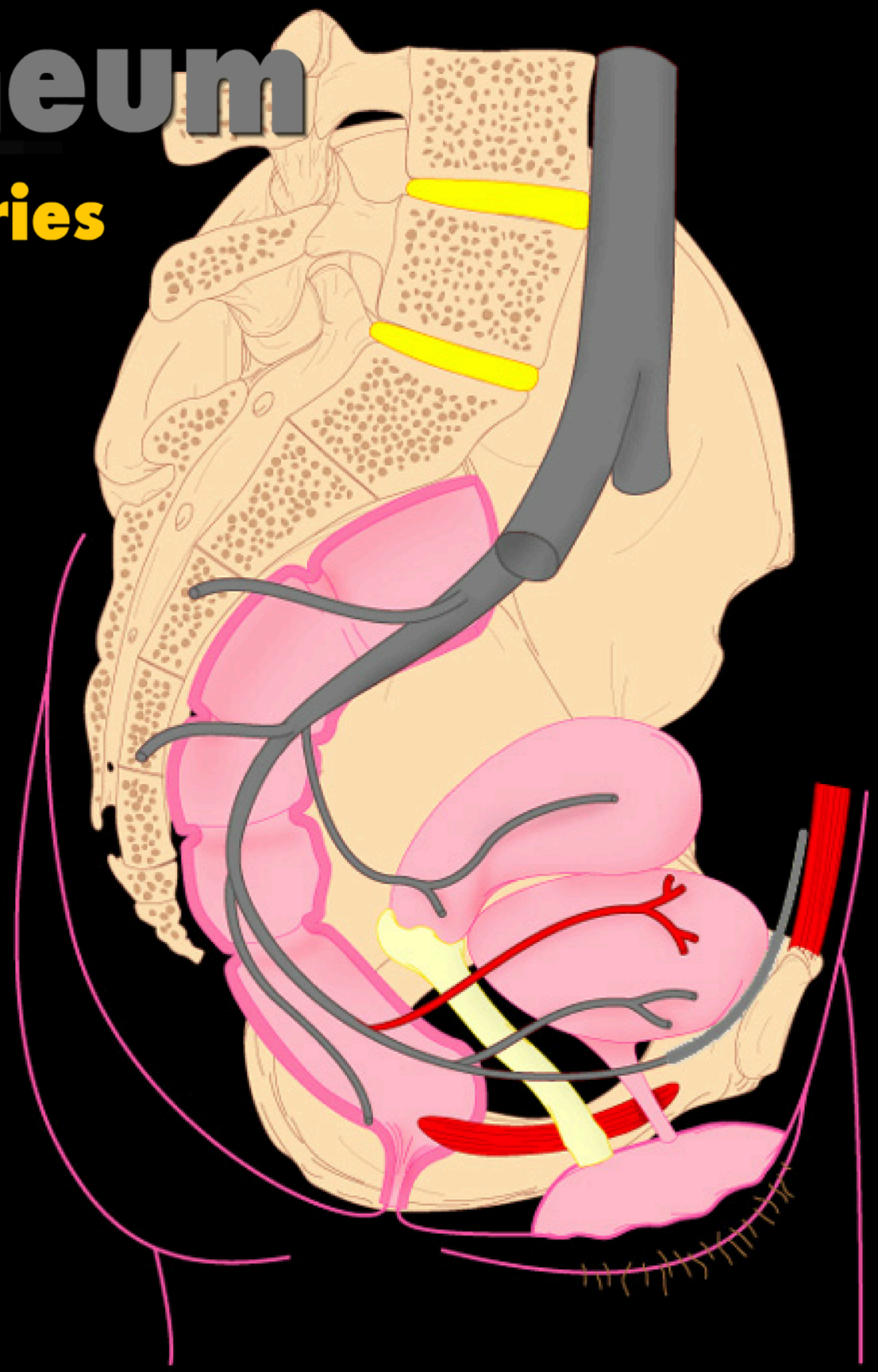

Pelvis/Perineal Blood Vessels

Internal Iliac Visceral Arteries

Inferior vesical artery

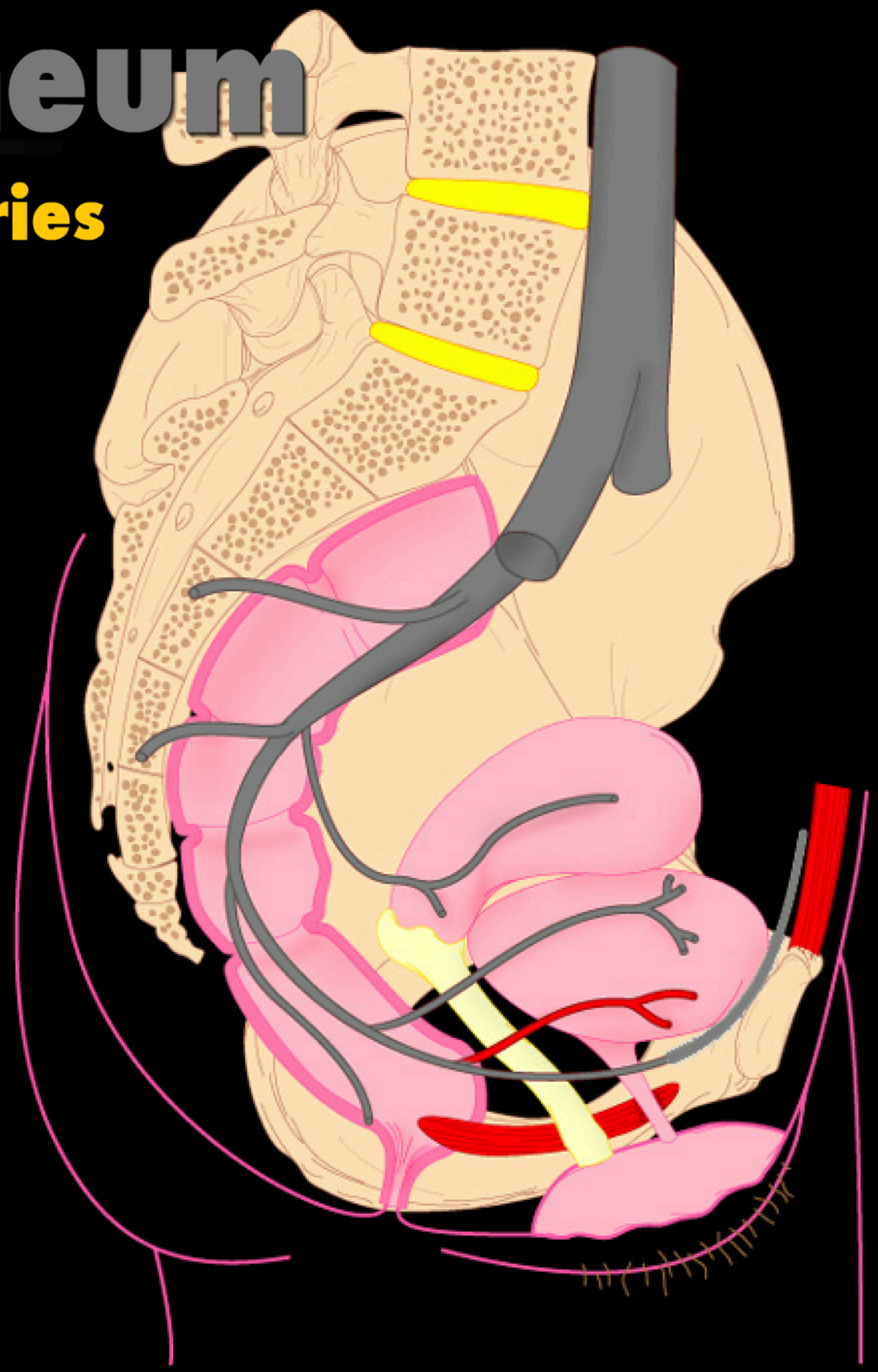

Pelvis/Perineal Blood Vessels

Internal Iliac Visceral Arteries

Uterine artery

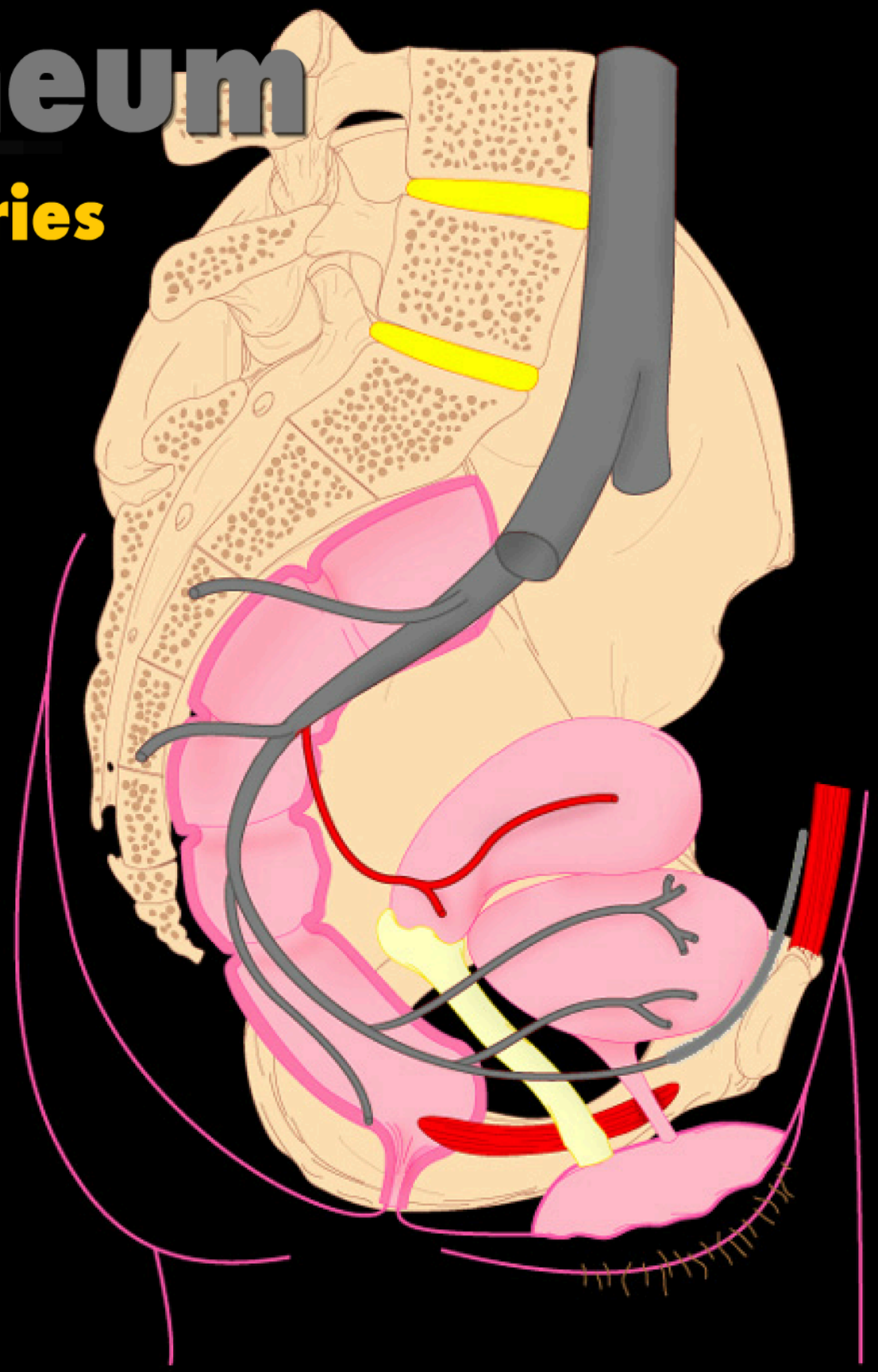

Pelvis/Perineal Blood Vessels

Internal Iliac Visceral Arteries

Obliterated umbilical artery

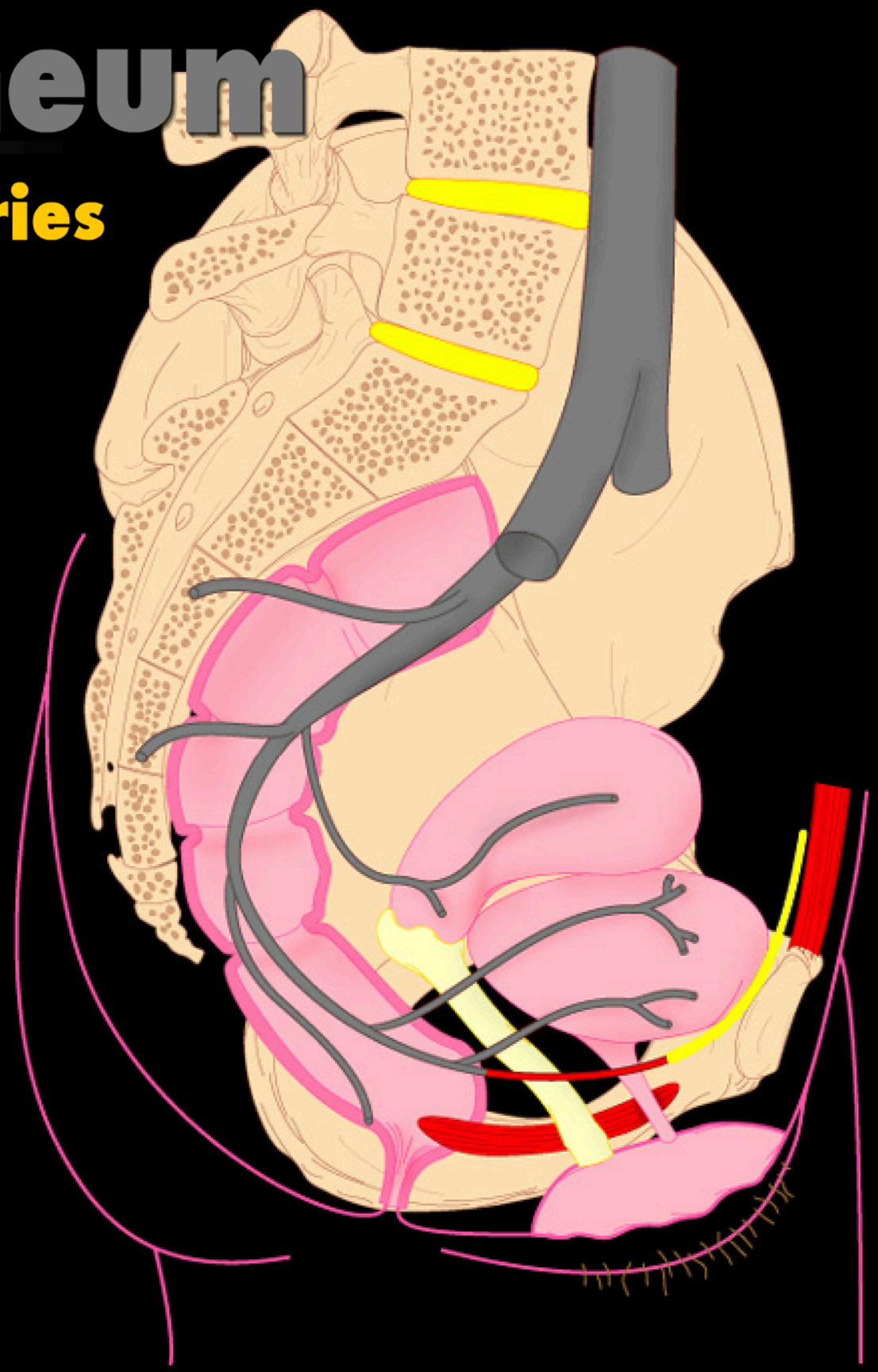

Veins of the Pelvis/Perienum

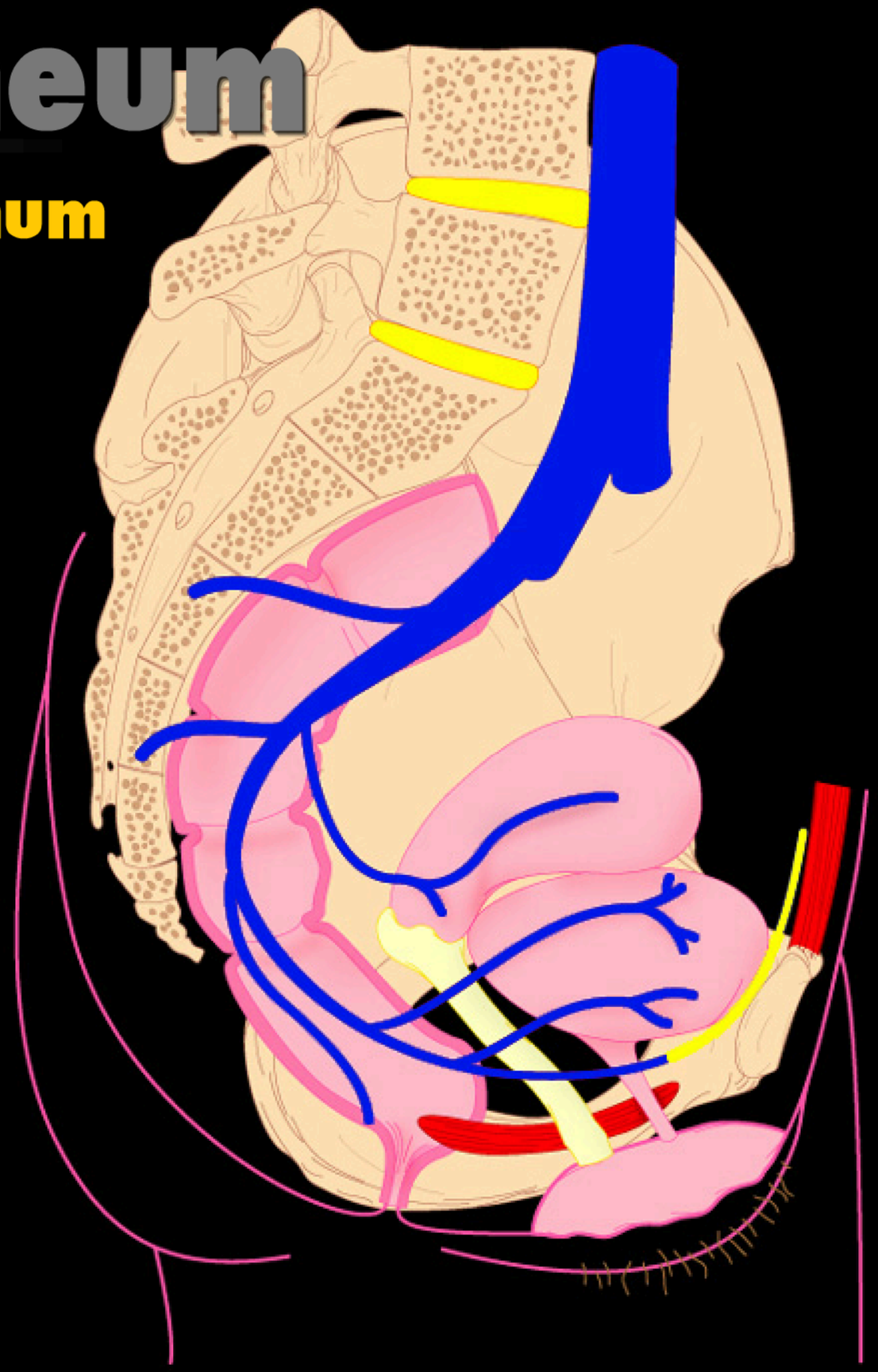

Pelvis/Perineal Innervation

Body Wall Nerves

Pudendal nerve

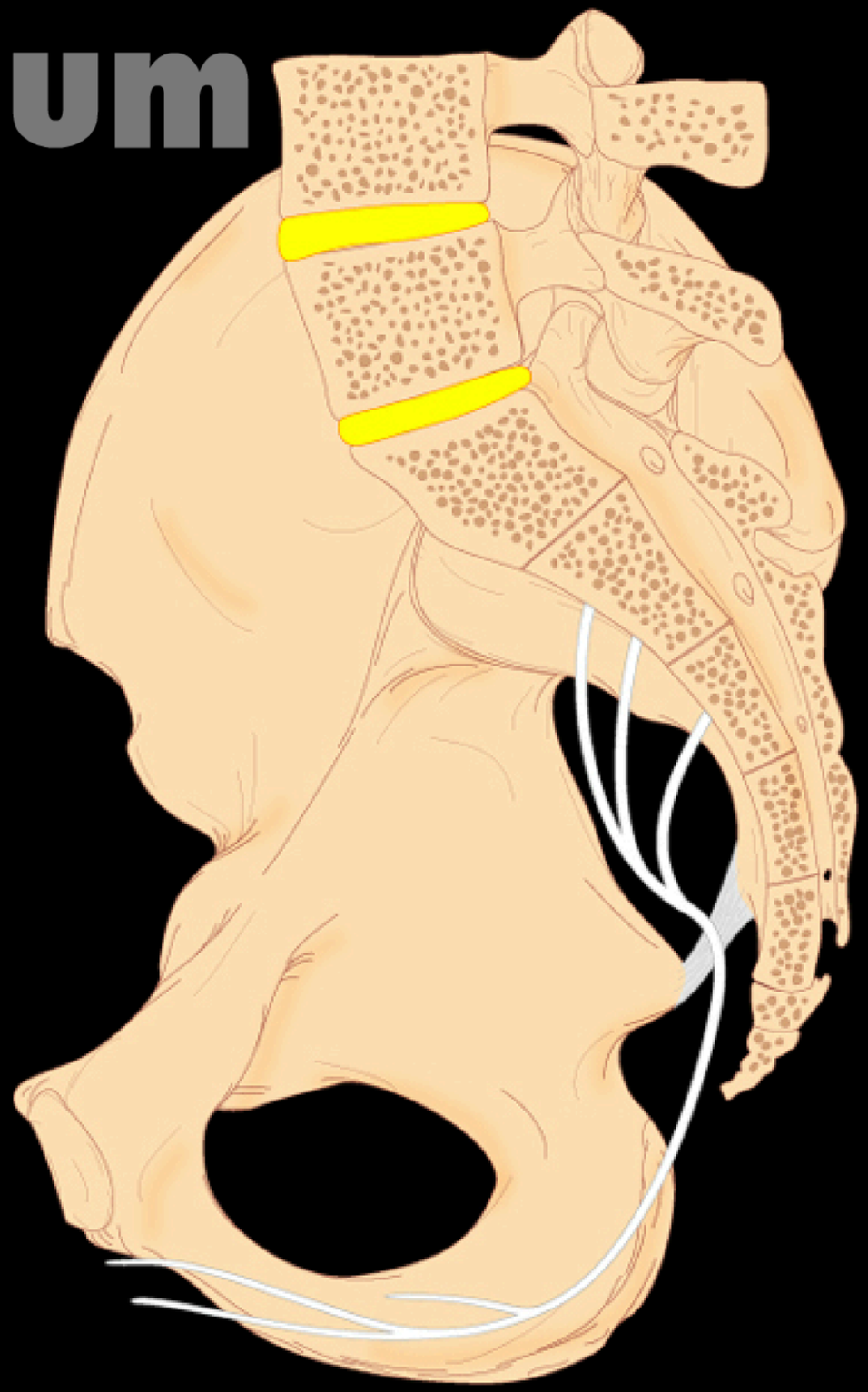

Pelvis/Perineal Innervation

Visceral Nerves

Sympathetic nerves

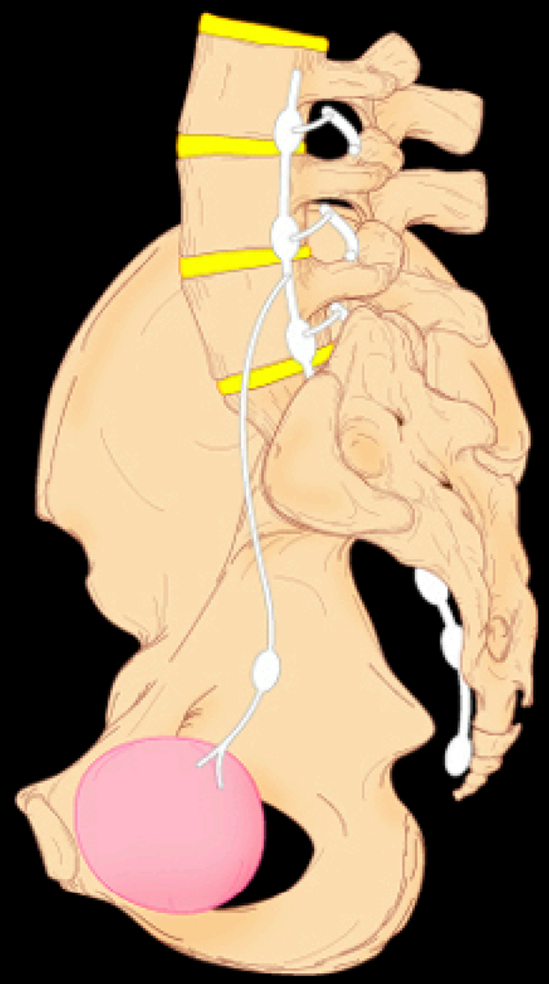

Pelvis/Perineum

Visceral Nerves

Parasympathetic nerves